

## Chapter 10: Radiology

Dental radiology is a very powerful tool. In order to make appropriate treatment decisions, we need an accurate assessment of the condition. In order to make an accurate assessment, we must have dental radiographs. This is not simply an option, *it is a requirement*, just as radiographs are required when assessing a limb fracture, a chronic cough or suspected intestinal obstruction.

Not only are radiographs essential in the diagnosis and monitoring of dental conditions, they are also a part of the medical record for legal purposes. Any practice offering any level of dental care should be routinely using dental radiography.

The good news is that the equipment and materials for dental radiography are not very expensive and the technique, once mastered, is quite simple.

### Dental Radiology Is Not:

- A luxury
- Technically difficult
- Just for dental experts
- An optional extra

### Dental Radiology Is:

- Absolutely essential
- Easy to learn and do
- Inexpensive and Profitable
- A medicolegal obligation

### Film

The film used in dental radiology is quite different from regular x-ray film. Firstly, it is non-screen film, meaning no intensifying screen is required. The film is most commonly available in three speeds, D-speed, E-speed and F-speed. Kodak calls each of these Ultra-speed, Ekta-speed and Insight respectively.

Ultra speed is fast film requiring exposure at low power. More importantly, its fine grain gives incredibly sharp detail of tiny dental structures, such as the pulp chamber in a cat's incisor tooth. Ekta speed film is twice as fast (so requires half the radiation) as Ultra speed but has coarser grain so what you gain in speed you lose in clarity. This is a trade off I am not willing to accept. As our veterinary patients will have far

fewer dental radiographs taken in their lifetime than their human counterparts, the saving in radiation exposure is less of a consideration. At least, that is what I used to say, until Insight film came along. Insight is as fast as Ekta speed but with image clarity that very closely approaches that of Ultra speed. I am using Insight and am happy with it despite the higher cost.

Each film packet contains the film inside a black card-paper folder. Behind this is a thin piece of lead foil to absorb scatter. If you put the film in the mouth with the back of the pack towards the X-ray beam, the beam must travel through the lead foil before it gets to the film. The result is a badly underexposed image. To help you identify the cause of the underexposure, the lead foil always has some sort of texture to it. This pattern will show up on your film and tell you that you exposed the lead. Now you know to try again with the same exposure settings, but with the film the right way around.

Dental film comes in a variety of sizes. I tend to use size 1 (1 1/2 X 15/16 inches), size 2 (1 5/8 X 1 1/4 inches) and size 4 (2 1/4 X 3 inches). Most film comes with one film per envelope. Two film packs have two pieces of film in each envelope so that each exposure gets you two identical images. This can be helpful if you want to send a copy of the film to a colleague or want to give the client a copy as a marketing tool. Duplicate films cost about 30% more than single film packs.

As to the cost of dental X-ray film, I will now quote from a human catalogue in Canadian prices. These prices are for Kodak Ultra speed film; house brands may be available at a lower cost. Some supplies may sell for more, others for less. Insight film is a bit more expensive. (Prices as of September 2001.)

code	size	#/box	price/box	price/film
DF-56	1, single	100	\$61.88	~\$0.62
DF-55	1, duplicate	100	\$77.44	~\$0.77
DF-58	2, single	150	\$59.95	~\$0.40
DF-57	2, duplicate	150	\$89.60	~\$0.60
DF-50	4, single	25	\$67.23	~\$2.70
DF-49	4, duplicate	25	\$88.67	~\$3.55

You can see from this that there is no financial excuse for holding off, especially when you

remember that these films need no cassettes, which are expensive and wear out with time. Since size-2 film is by far the most commonly used in human dentistry, it is the least expensive and it works well in most situations.

Dental radiographic film is not currently available from many veterinary suppliers, but it is available from some. It is also available from human dental suppliers so check your yellow pages.

### Exposure Suggestion

Most film boxes come with exposure suggestions printed on the side, but here are some example settings used to radiograph mandibular or maxillary canines using Ultra-Speed (D-speed). My dental X-ray machine is permanently set at 70 kVp and 7 mA, which is much weaker than general-purpose machines. The x-ray tube head is positioned very close to the patient so that the focal film distance is approximately eight inches. With these preset conditions, the only variable is exposure time.

cat/small dog	0.20 sec	1.4 mAs
medium dog	0.25 sec	1.75 mAs
large dog	0.33 sec	2.33 mAs

On a standard x-ray machine, the following suggestions (taken from *Atlas of Canine and Feline Dental Radiography*, Mulligan, Aller and Williams, VLS, 1998) may act as a starting point for developing a technique chart.

Patient	MA	KVp	Sec <sup>a</sup>	Sec <sup>b</sup>
Cat/small dog	100	50-60	0.1	.04
Dog under 30 lbs	100	60	0.1	0.4
Dog 30 to 60 lbs	100	60-70	0.1	0.4
Dog over 60 lbs	100	70-85	0.1	0.4

a: focal-film distance of 16 inches  
b: focal-film distance of 36 inches.

As there is no need for a focused lead grid with dental film, the tube-to-film distance is not critical. If your X-ray tube moves up and down, you can bring it to within 8 inches of the film. This allows for more accurate collimation and less scatter radiation. If your machine is bolted to the wall at 40 inches, no problem. You will still be able to take diagnostic dental radiographs at that distance.

Just remember that the intensity of radiation delivered to the target changes as the inverse of the square of the distance. So, if the proper exposure time is 1 second with a film-focal distance of 40 inches, then by reducing the distance by one half (to 20 inches), you can reduce the exposure time by one quarter (to 0.25 seconds). Put another way, if you double the focal-film distance, you must increase the exposure by  $2^2 = 4$ . If you triple the distance, you must increase the exposure by  $3^2 = 9$ . Therefore, the closer you can get the tube to the target, the lower the exposure settings you can use. Unfortunately, if you get the focal spot on the tube too close to the target, you will get a fuzzy image and excessive magnification.

In Figure #10.1, we see that with the cone at a greater distance from the tooth, the penumbra (fuzzy edge shown in grey) is smaller and the degree of magnification is less than with the cone closer to the tooth. Therefore, higher resolution requires a greater tube to film distance, which in turn calls for higher exposure settings.

Because there is no intensifying screen, the films can be packaged in individual vinyl or paper envelopes. These envelopes are flexible, allowing you to bend them to fit inside the patient's mouth. By using the intra-oral technique, it is possible to get very clear images of one or more adjacent teeth with no super-imposition of other cranial structures.

### Positioning

When taking a radiograph of a leg, the leg and film are arranged parallel to each other and the central X-ray beam is directed perpendicular to both. This gives an accurate image of the limb, both in terms of shape and size. In the mouth, it is often not possible to get film and tooth parallel and so we must use a different technique. The one employed is known as the *bisecting angle technique*.

The bisecting angle technique is used when radiographing any maxillary teeth and for the mandibular canines and incisors. For the mandibular premolars and molars, it is usually possible to place a dental film lingual to the mandible, and parallel to it, to employ standard parallel technique.

When it is not possible to place the film parallel to the tooth, there is an angle formed by the intersection of the plane of the film and the long

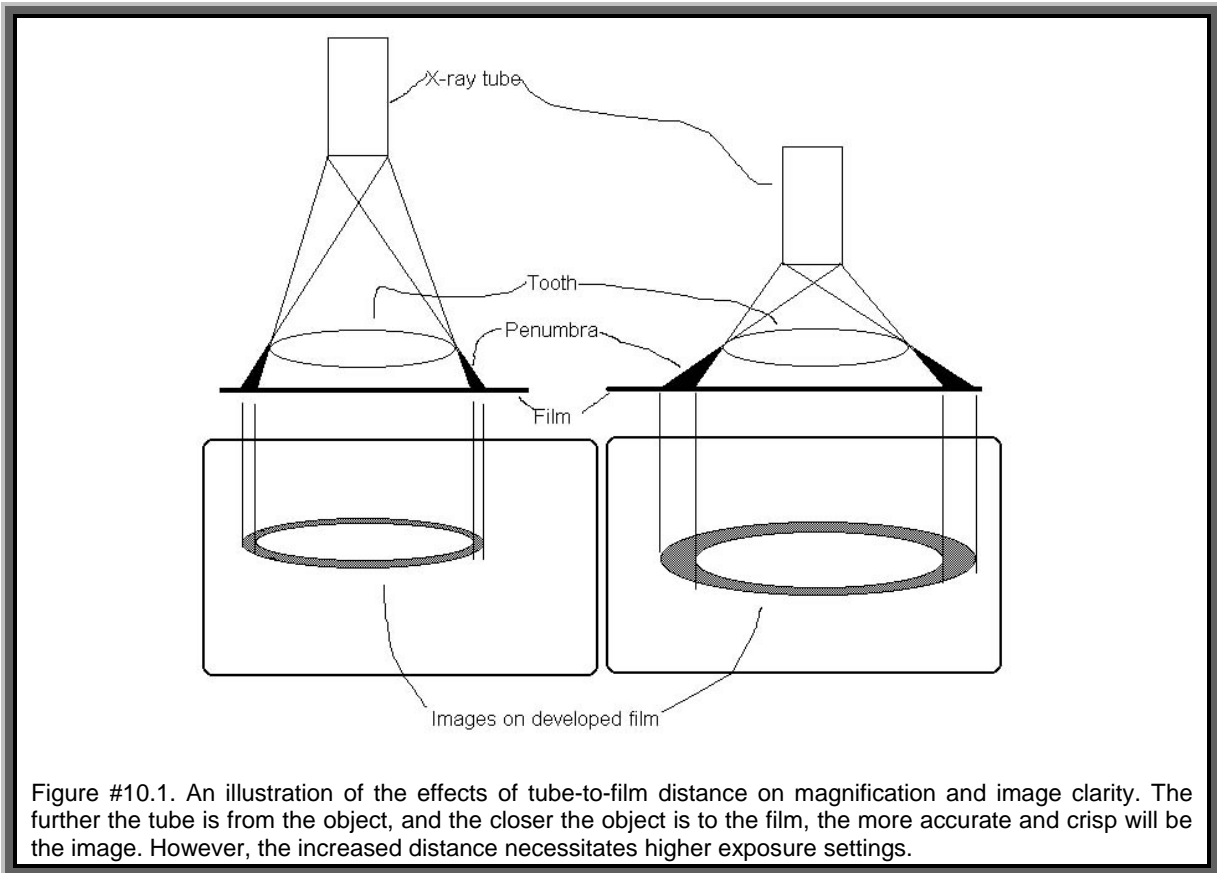


Figure #10.1. An illustration of the effects of tube-to-film distance on magnification and image clarity. The further the tube is from the object, and the closer the object is to the film, the more accurate and crisp will be the image. However, the increased distance necessitates higher exposure settings.

axis of the tooth. If the central x-ray beam is positioned perpendicular to the long axis of the tooth, the image on the film will be elongated. If the central beam is perpendicular to the plane of the film, the image will be foreshortened. If the central beam is perpendicular to a line that bisects the angle formed by the plane of the film and the long axis of the tooth, the image will be as accurate as possible.

Here is another way of looking at the bisecting angle technique. Imagine yourself standing on the beach as the sun rises. The shadow your body casts on the sand is much longer than your body (elongation). At noon, the shadow your body casts is considerably shorter than your body (foreshortening). At some point between sunrise and noon, your shadow would have been the same length as your body. Now, consider yourself to be the tooth, the sand is the film and the sun is the source of x-rays. At sunrise, the sun's rays are perpendicular to your body and the shadow is elongated. At noon, the sun's rays are perpendicular to the sand and your shadow is foreshortened. At midmorning, the sun's rays were perpendicular to an imaginary line that bisected the angle formed by the plane of the

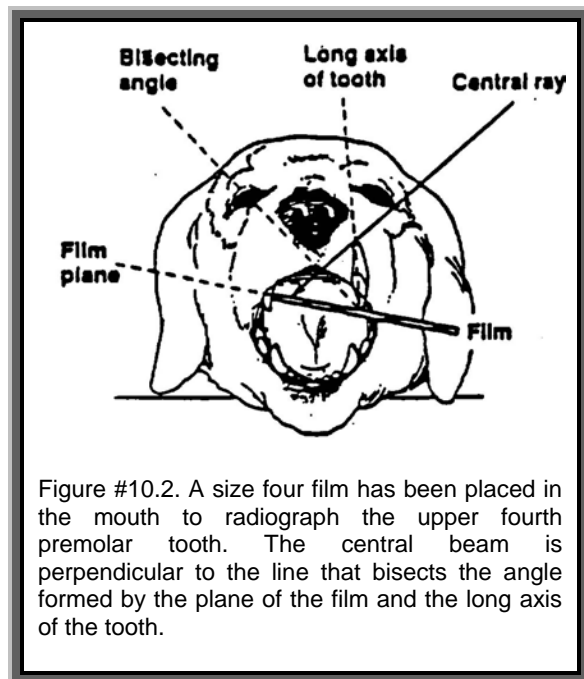


Figure #10.2. A size four film has been placed in the mouth to radiograph the upper fourth premolar tooth. The central beam is perpendicular to the line that bisects the angle formed by the plane of the film and the long axis of the tooth.

beach and the long axis of your body (the bisecting angle) and at that moment, the shadow

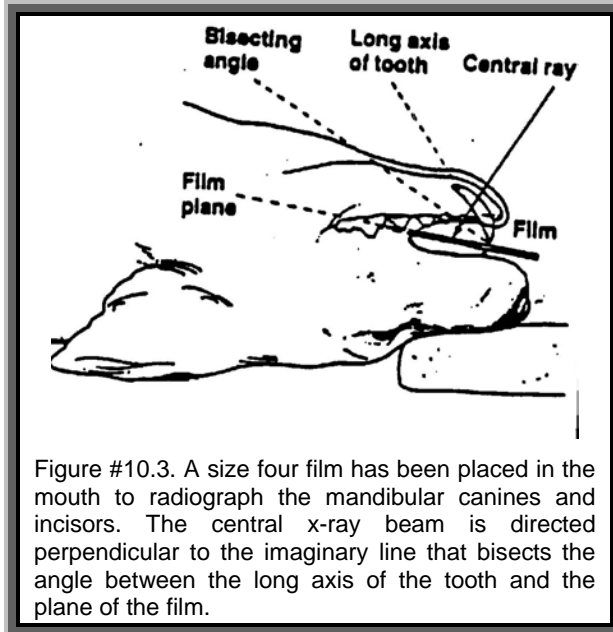


Figure #10.3. A size four film has been placed in the mouth to radiograph the mandibular canines and incisors. The central x-ray beam is directed perpendicular to the imaginary line that bisects the angle between the long axis of the tooth and the plane of the film.

was an accurate representation of the size and shape of your body.

The Bisecting Angle Technique uses the same principle in that the central x-ray beam is positioned to be perpendicular to the imaginary line that bisects the angle formed by the plane of the film and the long axis of the tooth being radiographed.

As the distance between the object and the film increases, so does the magnification of the image. With the bisecting angle technique, the tip of the tooth crown is right on the film, while root apex is some distance from the film. This causes magnification distortion of the apical area, but it is an artifact we must accept as inevitable with intra-oral technique. The advantages of intra-oral dental radiography make this distortion well worthwhile.

The upper fourth premolar tooth offers an extra challenge in that it has three roots. From a straight lateral view, the distal root is well imaged, but the palatal and mesiobuccal roots are superimposed and so are difficult to interpret. By using parallax shift, we can separate the roots on the film and see each one clearly.

Parallax shift is the apparent movement of distant objects as the viewer moves laterally. Again, use your imagination to follow this. Picture yourself standing at the edge of a very straight road, positioned directly behind a telephone pole. If you look at the pole with only one eye open, you will not be able to see the next




Figure #10.4. Film clips. The bottom one holds 10 films to hang for drying. The top three are single film clips for handling individual films during processing.

pole, as it is hiding behind the close one. If you take two steps to the left, the second pole now comes into view and it appears that, as you move further to the left, the near pole moves to your right and the second pole moves to the left with you. The distant object appears to shift laterally in the same direction as the viewer while near objects appear to shift in the opposite direction.

Now, if the x-ray beam is positioned directly lateral to the fourth upper premolar, the two mesial roots are superimposed. If the tube head is moved closer to the ear (so a caudal-to-rostral oblique angle), the far root (palatal root) will appear to also move caudally as the near root (mesiopalatal root) appears to move rostrally. This is the basis of the SLOB Rule, which stands for same=lingual; opposite=buccal. As the tube head is shifted either rostrally or caudally, the object (root) that appears to shift in the same direction as the tube head is lingual while the object that appears to shift in the opposite direction is buccal.

Another way to visualize this relationship is to hold up your right hand, with thumb and first two fingers pointing up and last two fingers folded in. Your fist represents the crown of the right upper fourth premolar, your thumb represents the distal root of this tooth, your index finger is the mesiobuccal root and your second finger is the palatal root. Looking at you hand with one eye closed, if you position yourself lateral to your hand, the second finger is hidden behind the first. If you move your head toward the thumb (caudally), the second finger comes into view and appears to move caudally as well (same=lingual), while the first finger appears to move rostrally (opposite=buccal). This same

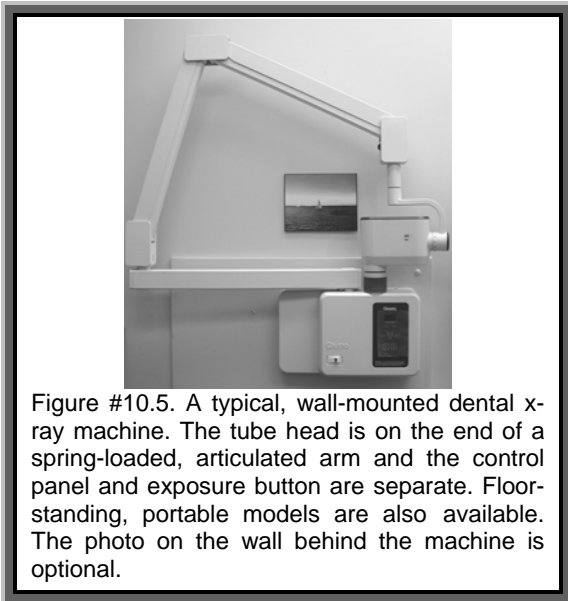


Figure #10.5. A typical, wall-mounted dental x-ray machine. The tube head is on the end of a spring-loaded, articulated arm and the control panel and exposure button are separate. Floor-standing, portable models are also available. The photo on the wall behind the machine is optional.

trick works with the left hand representing the left upper fourth premolar.

## The Machine

Can you take intra-oral dental radiographs with a standard x-ray machine? Yes, you can, but I do not recommend it. Typically, the standard x-ray machine is not right next to the dental treatment table, so each time a radiograph is taken, the patient and the anesthetic machine must be transported to the x-ray machine for the exposure. Then positioning of the patient and film relative to the machine can be tricky. All this makes taking dental radiographs with a standard machine less convenient than it should be and so the chances of taking a lot of films is not great. It is just too much of a hassle for most people.

By far, the best way to get dental radiographs is to have a dental x-ray machine mounted on the wall within easy reach of the dental treatment table. Then when a radiograph is indicated, it is a quick job to place a film in the mouth, position the tube head and take the exposure. From the time you decide you want a picture till you can read the film could be less than one minute.

There are dental x-ray machines marketed specifically for veterinarians, but as far as I can see, they have no advantages over machines marketed to human dentists. Though there may be some minor design differences between machines, they are all basically based on the same idea.

The tube head, which contains the anode and cathode that produce the x-rays, is on the end of

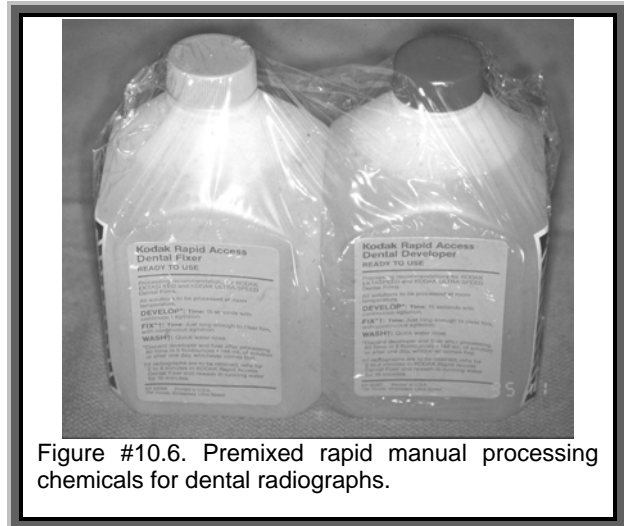


Figure #10.6. Premixed rapid manual processing chemicals for dental radiographs.

a spring-loaded, articulated arm. This allows the tube head to be moved and positioned for the desired projection without having to move the patient. A wall mounted control panel contains the timers and switches as well as the adjustment for the exposure time. Most dental radiograph machines have a preset mA and kVp so the exposure time is the only adjustable variable.

A brand new dental x-ray machine may cost between \$4000.00 and \$6000.00. There will be some installation costs and the wall to which it is mounted may require some bracing, but these are not big jobs. Since almost every dental patient requires dental radiographs, this is an investment that makes very good business sense as well as making good medical sense.

Placing a radiation source in your dental treatment area may require some effort to satisfy local regulations. Consultation with the inspectors before installation can help ensure that all goes well.

## Developing

How do you fit a tiny dental film into your 8 X 10 film hanger? You don't, of course. When it comes time to develop your dental films, you will want some dental film clips. You can get a box of twelve for about \$25.00. Each clip holds a single film securely and has a hook on the end of the handle so you can hang it up to dry the film. You could use a cheap pair of hemostats, but the chemicals will corrode them in a hurry.

You can develop your films in your regular bulk tanks. Just be careful not to drop them, because they can be difficult to retrieve from a deep, narrow developer tank. I prefer to have small pots of chemicals on the counter for developing

dental films. Tupperware, Rubbermaid, margarine tubs, mustard jars, anything with a plastic lid will do (metal lids corrode and are hard to get off).

Even better than using your regular chemicals is to use rapid dental developer and fixer. These chemicals are sold premixed and in sets. You can get a liter of each for about \$20.00. These rapid chemicals give finer detail on your films and allow you to develop, rinse, fix, rinse and read your film in less than 60 seconds. That's fast. (After reading the films, they should go back in the fixer for at least 5 minutes and then be rinsed in water for 20 minutes before drying and storing).

Automatic processors are available for small dental films. They will provide consistently processed and dry films in about 3 to 5 minutes. When I am doing intra-operative films for root canal treatment, this is too long for me to wait, but in many cases an automatic processor would be a good option.

### Orientation of Processed Films

Suppose you are taking a whole-mouth series of a cat prior to treating a mouth with multiple resorptive lesions. This series would employ at least 7 films; one for each mandible, one for each maxilla, one for the mandibular canines and incisors and one for each of the right and left maxillary canines and incisors. You have taken these 7 exposures on size 1 or 2 film and have developed them at one time. Now you have a hand full of films and you must decide which is which. You should be able to recognize the anterior mandibular view and the anterior maxillary views and you should be able to tell a posterior mandibular view from a posterior maxillary, but how do you tell left from right. The films are much too small to place a lead marker on them. Fortunately, the filmmakers have foreseen this dilemma and have a solution. On the back of each film packet there is a circle or a dot. The location of this marker corresponds to a bump on the actual film inside.

*You should position the film so that this marker is always at the nose end of the film.* When the film has been developed, hold it so that the bump is raised towards you. Now you know you are looking at the film from the correct side, and the bump tells you which end is rostral, so you can figure out which side of the head you are looking at. Once you have tried this a few times, you will see how easy it is.




Figure #10.7. A chairside darkroom. The plastic lid filters light that would affect the X-ray film so you can watch what you are doing. Your hands go in through the diaphragms, which fit tightly around your wrists to block out room light. Inside are pots with the processing chemicals.

### Indications

Now that you have the film, chemicals, clips and technique chart, you need to find a situation that calls for a dental radiograph. Actually, this is the easiest part. When I first started playing with dental radiography, I took only the occasional radiograph. As time went by, I noticed that most of the radiographs I took told me something of great value. It made me think I should be taking more, as there might be other valuable information that I was missing.

The radiographs you take are used to assess the condition of the tooth root's internal and external anatomy and the bone supporting them. Anytime you want to see what is going on inside or around a root, take a radiograph.

Here is a partial list of indications for taking a dental radiograph.

X-ray the areas where there are “missing” teeth that you have no record of extraction. Maybe the teeth are present but impacted or maybe there is a retained root fragment from a previous fracture or extraction.

X-ray chipped teeth without obvious pulp exposure. Radiograph the crown to see how much dentin there is between the pulp and the outer surface of the fracture site. If there are 2 millimeters or more of dentin then the tooth might be fine with no treatment. If there is less than this amount of protection over the pulp then a pulp-capping procedure may be indicated. Also radiograph the root and peri-apical area to look for evidence of endodontic or periapical disease. If there is doubt as to whether there is a pathological change, radiograph the contralateral counter-part and compare the two.

X-ray fractured teeth with obvious pulp exposure. Radiograph the root and peri-apical area to assess the amount of peri-apical disease. Some teeth will have such extensive root resorption as a result of endodontic infection that extraction is the only possible treatment. Many others can be treated with standard endodontic therapy or surgical endodontics.

X-ray every tooth in a cat that has a history of resorptive (neck) lesions. I have often found severe root resorption in cat teeth whose crowns appear perfectly normal. By doing a whole mouth survey (typically six to eight films), you can be sure of finding every tooth which requires treatment.

X-ray any tooth you plan to extract. Some roots have curved or bulbous tips which can lead to root fracture if care is not taken. Some teeth have undergone ankylosis of the periodontal ligament, making extraction very challenging. Some teeth have extra roots. Having a pre-operative radiograph lets you know what you are getting into so you can approach the extraction in the proper manner. This radiograph also serves to document the reasons for extraction should the client question the decision.

A post-extraction radiograph is a good way to document that the entire root has been removed and that there are no retained root fragments.

Radiography is a useful tool in assessing the periodontal status of a tooth. It shows how much and what pattern of bone loss there has been. This information will help determine prognosis and direct treatment planning.

You will probably find other uses for dental radiology after you get comfortable with the technique. Actually, the size four films are very useful for radiographing hamsters, gerbils, canaries, paws, tails or anything small where you want a very fine-grained image.

I could fill a book with examples of dental radiographs that gave me information vital to the assessment and treatment of patients. There are currently two atlases of veterinary dental radiography/radiology in print that are just that – books full of dental radiographs. The point is, radiographs are essential and should be standard procedure in all general practices.




Figure #10.8. This “Step-Wedge” is used in radiographic quality control. It is radiographed using a standard technique and the film processed. The image should show ten distinct shades of gray from dark to light moving up the wedge. The film around the wedge should be black and the top step almost white.

## The Future of Radiography?

For some time, digital dental radiology has been available, though quite expensive. It involves a small, charge couple device (CCD) about the size of a size 2 dental film, which is attached by a cord to a computer. Positioned exactly like a piece of dental film but exposed to a much less radiation, a digital radiograph is generated and appears on the computer screen in one to four seconds. The image can then be enhanced in a variety of ways to aid interpretation.

Advantages of digital dental radiography include:

- The claim that exposure required may be as little as one tenth that needed for D speed film.
- Images ready almost instantly with no processing delay or errors.
- No need to stock film and chemicals.
- Digital images do not decay.
- Images instantly ready for email or inclusion in referral letters or discharge statements.

As the price drops and technology improves, this will likely replace film and chemicals for many applications. However, the lack of a size-four sensor means that even digital practices will likely have to stock size four film and have a method of processing and storing these larger images.