

## LIP ENTRAPMENT

### A POSSIBLE COMPLICATION

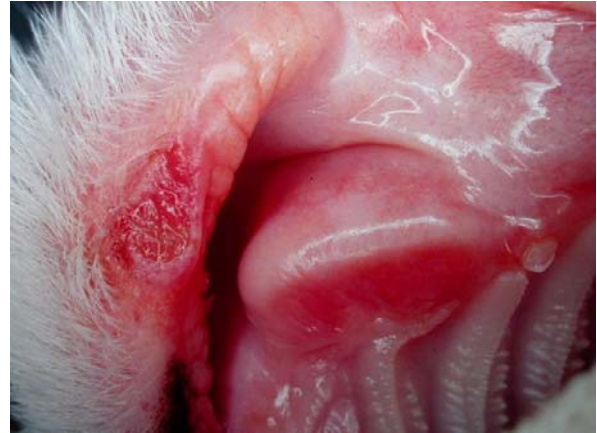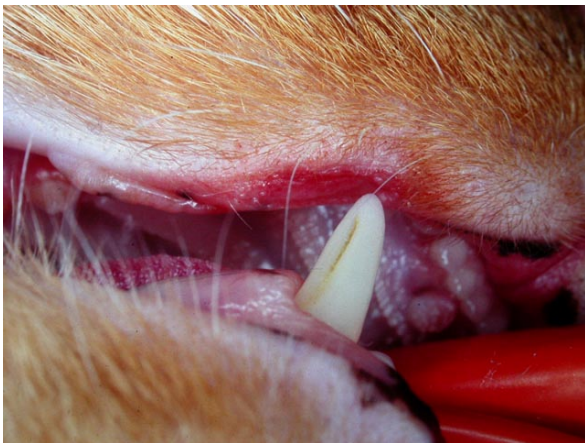When deciding on whether to extract a tooth or not, there are many factors to consider. Among these is, “How will the loss of the tooth in question affect the form and function of the mouth?”

If a dog loses a lower first premolar tooth, there really is no significant change to the form and function of the mouth and so it is not a major factor to consider. On the other hand, if a cat loses its upper canine tooth, this can have serious consequences.

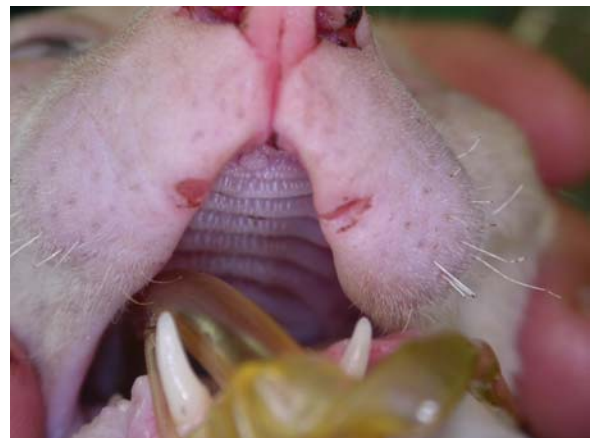A cat’s upper lips tend to be fairly tight to the face. The presence of the crown of the upper canine tooth then holds the lip out so that when the mouth closes, the lower canine tooth can slip up inside the upper lip without causing trauma.

If a cat has to lose an upper canine tooth (due to end-stage periodontal disease, tooth resorption...), there is a tendency for the upper lip to sink in. Then the lower canine will bite/pinch/traumatize the upper lip each time the cat closes its mouth. Some cats seem to learn how to close their mouth without biting themselves, but many do not.

The cats in the first two photos had each lost an upper canine tooth. The chronic ulcers on their lips were the result of trauma from the lower canine tooth biting the upper lip.



The rex in the following photo had lost both upper canine teeth and so had bilateral traumatic lesions from contact by the lower canine teeth.



Prevention is the best policy. Therefore, when possible, it is preferable to treat and preserve upper canine teeth in cats rather than extracting them.

If an upper canine tooth has suffered a fracture, doing (or referring for) root canal treatment will preserve the root and as much of the crown as remained after the fracture. This is usually enough to keep the upper lip out of harm’s way.

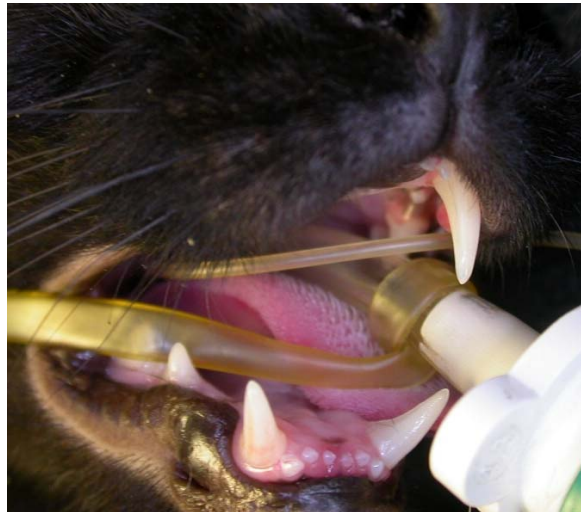
Since it is not always possible or practical to preserve the upper canine tooth, we also need a plan B.

My approach is as follows. If the upper canine tooth is beyond repair and must come out, I carefully assess the ipsilateral lower canine tooth. If it has any pathology at all (periodontal disease, evidence of tooth resorption) I will remove it as well and thereby prevent it from causing trauma to the upper lip.

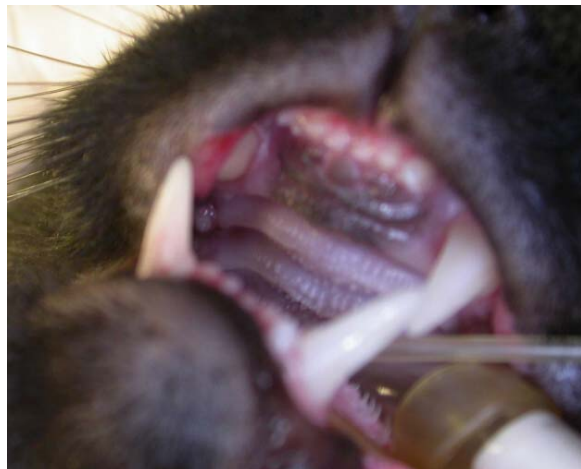If the ipsilateral lower canine is 100% healthy, then options include:

- do nothing and hope that the cat learns how to close its mouth without biting itself, realizing, and explaining to the owners that problems might arise and further treatment might be required,
- preemptively do crown reduction and root canal therapy on the lower canine tooth,
- preemptively extract the lower canine tooth.

I have had one case in which doing root canal treatment on the upper canine tooth did not prevent lip entrapment. In this cat, the remaining length of the crown of the upper canine tooth was insufficient to keep the upper lip out of the way...



... and so the cat was presented about 10 days post-op with a painful traumatic ulcer on the upper lip.



Options at this point included crown reduction and endodontic therapy of the lower canine or placement of a cast metal crown on the upper canine to increase crown length to keep the upper lip out of the way. For various technical and practical reasons, we opted to extract both the upper and the lower canine teeth to resolve the issue.