

FOCUS ON: CHRONIC ULCERATIVE PARADENTAL STOMATITIS AKA CUPS.

This is one nasty and frustrating condition! As well as being referred to as *CUPS*, it may also be called *ulcerative stomatitis*, *idiopathic stomatitis* and *lymphocytic-plasmacytic stomatitis*. This multiplicity of labels is a reflection of the lack of solid understanding of the cause(s) of the condition.

Before going any further we need to make a clear distinction between periodontal disease and paradental disease.

Periodontal disease affects the four periodontal tissues (gingiva, alveolar bone, periodontal ligament and cementum on the root). More on those tissues can be found and reviewed at: www.toothvet.ca/PDFfiles/PerioAnat&Physio.pdf.

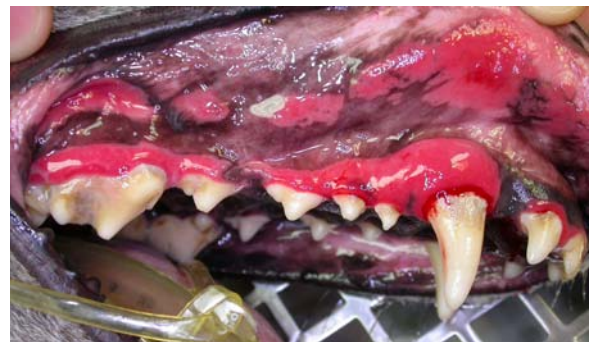The paradental tissues are the other soft tissues that share the oral cavity with the teeth and which often lie in contact with the crowns of the teeth when the mouth is closed. This includes the oral mucosa, the palatal mucosa, the lining of the buccal pouch, the margins of the lips and the epithelium of the tongue. In many patients, these paradental tissues can remain relatively healthy even in the face of chronic and advanced disease of the periodontal tissues. On the other hand, a patient may have severe CUPS with relatively good periodontal health. They really are two separate conditions that may be present on their own or concurrently.

Certain breeds such as Maltese terriers and Cavalier King Charles Spaniels are reported as being over-represented and in my own experience, I would say Greyhounds also seem more susceptible than the general population. That said, I have seen the condition in a wide variety of breeds and sizes.

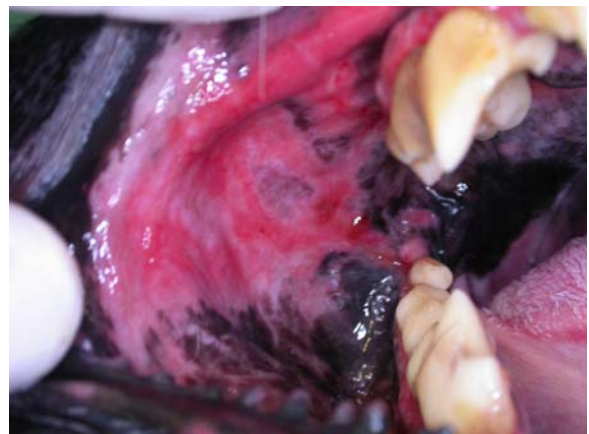
Presenting complaints may variably include any or all of: severe halitosis (though you would be surprised what some owners can get used to), excessive drooling of thick, cloudy saliva, lip-fold dermatitis, oral pain and difficulty eating.

This first photo is of a mature, rescued Greyhound prior to first treatment. There is

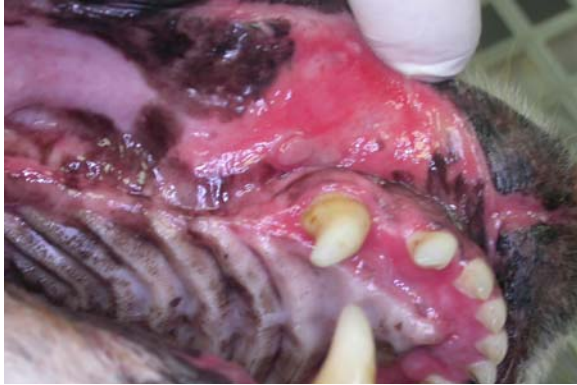certainly periodontal disease with marked, generalized ulcerative gingivitis and gingival recession at the posterior teeth visible on conscious examination. Note the intense inflammation and ulceration of those areas of oral mucosa that lie against the crowns of the teeth. These are referred to as *contact ulcers* or “kissing” ulcers.



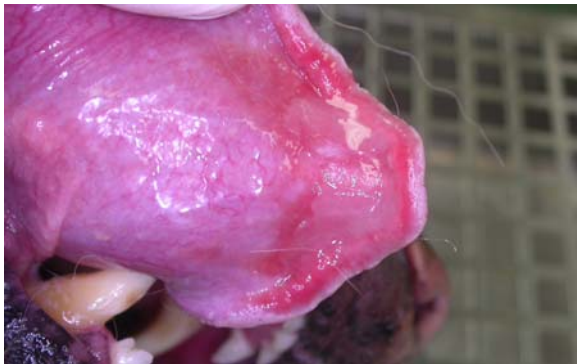This next photograph is of the right buccal pouch in a mature German shepherd dog. Again, ulceration and inflammation of the buccal mucosa is apparent.



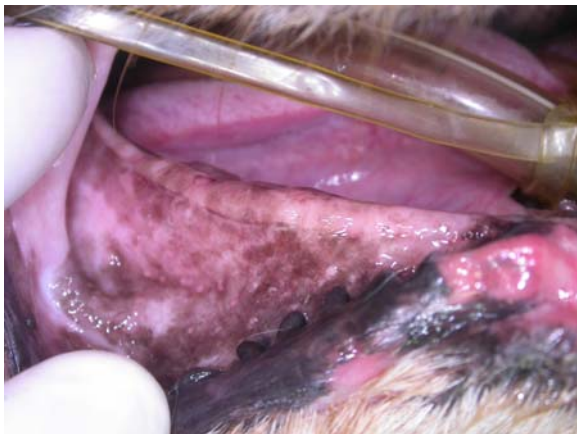Next, we see contact ulcers just around the area of the maxillary canines and incisors, because the posterior teeth have all been extracted some years prior. This patient is a geriatric Nova Scotia Duck Tolling Retriever. Note the ulceration and inflammation of the palatal mucosa as well.



The ventral lingual mucosa in this NSDTR's mouth was also ulcerated and inflamed from lying in contact with the mandibular incisors.



Yet this edentulous (toothless) area (right mandible) is free of lesions.



The differential rule-outs would include various immune-mediated diseases such as the variations of pemphigus and bullous pemphigoid. While these conditions can result in oral lesions, they also often are associated with lesions of the skin and mucous membranes in other areas of the body. Therefore, a thorough examination of the entire patient to look for other areas of involvement should be under-taken. Since the

treatment for the immune-mediated diseases is very different from the treatment for CUPS, it is important to make the distinction early on in the management of the case.

As well as a complete physical examination, CBC and biochemistry are good to have pre-operatively. The only laboratory findings typically associated with CUPS is a (polyclonal) hypergammaglobulinemia and a mild neutrophilic leukocytosis, so any other abnormalities should be assessed in their own right before anesthetizing the patient.

While a biopsy of the affected tissues would be a good thing to have, to rule out an auto-immune disease, this requires an anesthetic and so I would always suggest that far more than a biopsy be done at that time.

The only lab finding typically associated with CUPS is a (polyglonal) hypergammaglobulinemia, as expected with any chronic inflammatory disease.

While the specific pathogenesis of CUPS remains unknown, it is helpful to consider that, for whatever reasons, these animals are unable to tolerate the presence of bacterial plaque on the crowns of their teeth. Even fairly minor plaque accumulations result in an over-blown, destructive (and painful) ulcerative inflammatory response. Therefore the focus of the management of CUPS must be scrupulous plaque control. Starting on page three of <http://toothvet.ca/PDFfiles/HomeCarePack.pdf> you will find a brief explanation of plaque and the rest of this package discusses various plaque-control strategies and challenges.

Following a complete physical examination, CBC and biochemical profile, if things are pointing to CUPS, the next step is a COHAT (comprehensive oral health assessment and treatment). This starts with a detailed examination, probing and charting of each and every tooth along with whole-mouth intra-oral dental radiographs. All teeth with significant periodontal disease (pocketing, bone loss, furcation exposure) or endodontic disease should

be extracted. Selective extraction in areas of crowding (that would be plaque-retentive) would also be indicated. All extraction sites are sutured with an absorbable monofilament (I favor 5-0 and 4-0 Monocryl™). The remaining teeth are then cleaned thoroughly above and below the gum line. This is also when you would get your biopsies. Then polishes and lavage. In areas where it is available, I would recommend applying a coat of Merial's Ora-Vet™, which is a waxy coating for the teeth that will inhibit bacterial recolonization of the crowns of the teeth (<http://www.oravet.us.merial.com>). At the time of writing, this product is not available in Canada.

Our highest priority in veterinary dentistry is to provide for our patients a mouth free of pain and infection. This objective must supersede all other hopes and expectations.

The next phase is tricky. In most cases, the patient will have had some extractions and we need those sites to heal. Also, the mouth has already been sore for a long time and so the animal is going to be mouth-shy. Therefore, I do not want the owners touching the mouth at all for two weeks. I don't want the owners causing the animal further pain and I do not want them applying any pressure or tension on the incisions as this may disrupt healing. I do want the patient on analgesics for several days post op and I will probably also dispense antibiotics (I send antibiotics home only rarely, but these cases do call for it). Since I don't want the owners handling the mouth, the medications must be taken voluntarily by the patient and so must be in a form or disguised in a way that the animal will gladly ingest them.

Following a two-week healing period we hit the even trickier part. The owner must now institute a very aggressive plaque control program or you can expect the patient's condition to return to pre-op status within a very short time. The most effective way to do this is for the owners to brush the teeth daily with a nylon-bristled tooth brush. As the Home Care documents previously cited indicate, it is the mechanical action of the

tooth brush that does the work. All the rinses and gels and pastes and water additives in the world will not control plaque to a sufficient degree to do the job in these patients. They may be useful adjuncts, but the toothbrush is the cornerstone of this program and must be used daily. No rinse, paste, gel or water-additive will come close to keeping CUPS under control if not used with the daily application of a tooth brush.

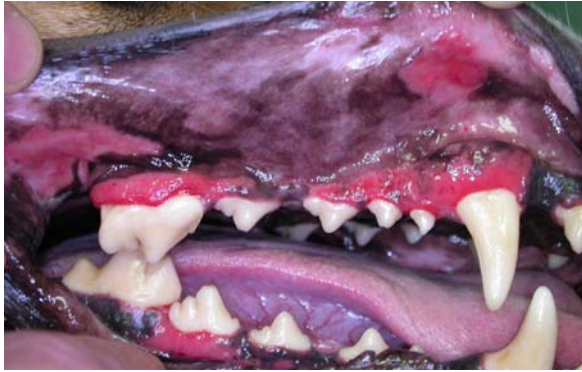In domestication, dogs do not need to hunt and kill their own food, they do not need to rend raw meat from a carcass. The food is dead and in the bowl ready to swallow.

As well as daily brushing, the weekly application of the home care version of Ora-Vet™ (where available) is indicated. When dietary issues do not preclude it, I would also recommend feeding a diet shown to aid in the reduction of plaque. A listing of diets that have been proven to offer measurable plaque-control benefits can be found at the website of the Veterinary Oral Health Council (www.vohc.org). Diets that have received the Seal of Acceptance for tartar only are not good enough here. We need plaque control! At time of writing, the only canine diets with the Seal of Acceptance for plaque and tartar are Hills™ Science Diet™ Canine Oral Care™ and Hills™ Prescription Diet™ Canine t/d™.

In domestication, dogs do not need to defend territory or protect themselves from predators. We provide them with walls, a roof and fences for protection.

If everything goes really really well, plan on doing COHATs every six to twelve months for as long as the patient has teeth. No matter how well the owners are brushing, no matter if they are using Ora-Vet™, no matter what they are feeding their pet, no combination of home plaque control strategies will be completely effective and the patient is going to need your

professional help as well to keep the wheels from falling off.



This photo is of the Greyhound from page 2 at a one-year follow-up. The owners had been doing a good job of home care and while the ulcers are smaller and far less “angry” looking, there is still plenty of inflammation.

In domestication, dogs do not need to establish breeding rights. They are either neutered or are allowed to breed under controlled conditions.

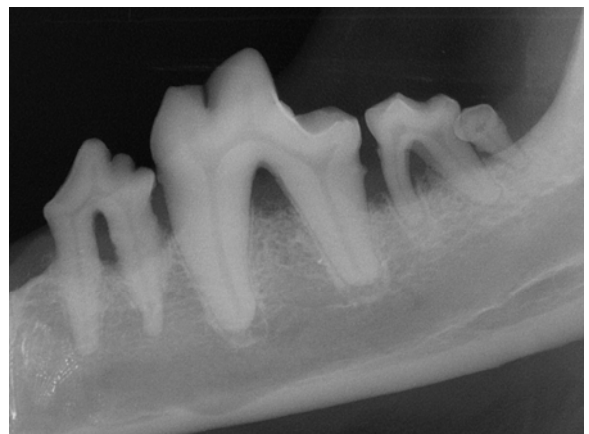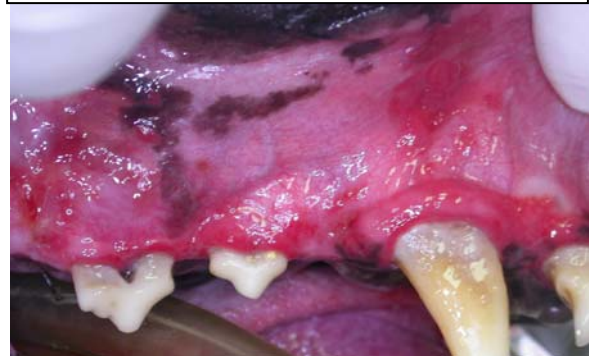By this point, you may be asking if there is a Plan B. Well, the good news is that there is an alternative. The other good news is that this alternative treatment often gives far superior results in both the short term and in the long term. The bad news is that it is a big job. I am referring to whole-mouth extraction.

In my referral practice, by the time these animals reach my door, the simple things have been tried and have failed. I see the refractory cases and so my perspective may be a bit skewed, but for most of my CUPS patients, whole-mouth extraction is the right thing for me to do no matter how much the owners might think they want to try to save teeth.

CUPS is often concomitant with periodontal disease (gingival recession, bone loss, pocketing) and so even if the inflammation could be magically turned off like a light switch, many teeth are going to require extraction anyway due to irreversible periodontal tissue loss.

In this mature Greyhound, we see not only CUPS, but obvious periodontal disease.

In domestication, dogs do not need teeth. What they need and deserve is a mouth free of pain and infection.



In a case like this, there really is no point in trying to save any teeth. They are almost all beyond hope. There might be one or two that are not completely over the edge yet, but they are not going to be of any value to the patient and are only going to be an ongoing liability, so the rational approach is to just clean house and be done with it.

Now, aside from whole-mouth extraction or fanatical plaque control, is there no Plan C? Unfortunately, at present, there is not. Until we know why the local immune response to plaque is so out-of-control and until we can reliably calm it down without causing a host of other problems, we need to get the mouth plaque-free and keep it that way. There are no short-cuts and no miracle drugs for this one. While some medications (antibiotics, anti-inflammatories, immune-system modulators) may offer temporary symptomatic relief, none have lasting effect and all have undesirable side-effects. The treatment for CUPS does not come in a bottle.