





















# Radiographic Notes - Canine

## Right maxilla

Findings

Findings

## Left maxilla















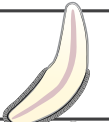







|   |  |  |   |
|---|--|--|---|
|  101  |  |  | 201   |
|  102 |  |  | 202  |
|  103 |  |  | 203  |
|  104  |  |  | 204  |
|  105 |  |  | 205  |
|  106  |  |  | 206  |
|  107  |  |  | 207  |
|  108  |  |  | 208  |
|  109  |  |  | 209  |
|  110  |  |  | 210  |

## Right mandible

Findings

Findings

## Left mandible

|   |  |  |   |
|---|--|--|---|
|  411 |  |  | 311  |
|  410  |  |  | 310  |
|  409  |  |  | 309  |
|  408  |  |  | 308  |
|  407  |  |  | 307  |
|  406  |  |  | 306  |
|  405 |  |  | 305  |
|  404  |  |  | 304  |
|  403 |  |  | 303  |
|  402 |  |  | 302  |
|  401 |  |  | 301  |