







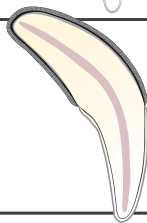
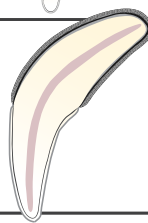


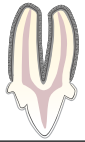
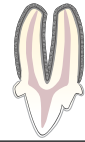




# Radiographic Notes - Feline

## Right maxilla

Findings

Findings

## Left maxilla

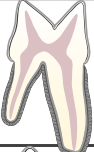
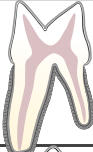



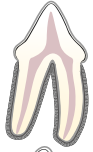
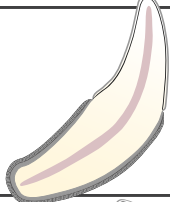
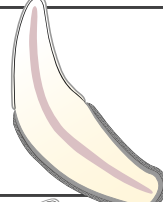





 101			201 
 102			202 
 103			203 
 104			204 
 106			206 
 107			207 
 108			208 
 109			209 

## Right mandible

Findings

Findings

## Left mandible

 409			309 
 408			308 
 407			307 
 404			304 
 403			303 
 402			302 
 401			301 