







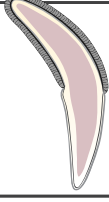
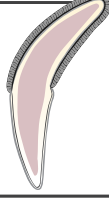






Radiographic Notes - Feline Deciduous

Right maxilla

Findings

Findings

Left maxilla





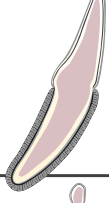
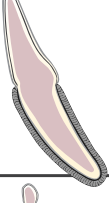





 501			601 
 502			602 
 503			603 
 504			604 
 506			606 
 507			607 
 508			608 

Right mandible

Findings

Findings

Left mandible

 808			708 
 807			707 
 804			704 
 803			703 
 802			702 
 801			701 