



A PICTURE IS WORTH...

In a previous paper, I mentioned the value of sharing good clinical photographs when looking for advice on a patient/your pet (www.toothvet.ca/PDFfiles/camera.pdf). In this piece I want to outline, in more detail the value (and limitations) of good photographs with some examples of the types of images we are looking for and how we prefer you send them to us. I will also be talking a bit about sharing intra-oral dental radiographs, whether you are sharing them directly with me or on web-based forums (VIN for example).

See page 6 for a summary of the steps to follow.

Limitations:

I should mention that nothing beats me seeing the pet, live and in 3-dimensions and depending on the problem and the quality of the images sent I sometimes have to say “that does not tell me enough to give you a confident interpretation”. However, there are many times when some well-done image can make a huge difference in my understanding of the situation, allowing me to offer useful advice and/or to triage the case appropriately. For instance, a mass that looks “hot” would get priority scheduling compared to something that looks very bland.

Photographs can show me the outside of the crowns of the teeth and the surrounding soft tissues. They cannot show me the inside of the

teeth, the roots of the teeth, the bone below the soft tissue, the depths of defects, the texture of the tissues. Photographs do not allow me to touch, manipulate, probe, explore around the area of interest. There is a lot of information I cannot get from photographs, so there are certainly limitations.

If photographs are accompanied by good-quality, diagnostic intra-oral dental radiographs, their value goes up dramatically (and vice-versa – the value of radiographs is often enhanced by having accompanying clinical photographs to go with them).

What to send along with the images:

If you are a veterinarian and are planning on sending me some images (photographs and/or radiographs), even if you are just looking for advice, please also include a completed referral request form so we have signalment and other important information to aid in the interpretation. A link to and instructions on using that form are available here:

www.toothvet.ca/PDFfiles/how_to_refer.pdf.

If you are a pet owner looking for advice, please complete the client-patient form and send it to us. Here is the link:

www.toothvet.ca/PDFfiles/client_pat_info_fillable_2020.pdf.

When to send us Images:

This list could go on for pages, but I will focus on a few specific examples to get the ball rolling.

Malocclusions.

Orthodontics is a game of millimeters and in young, growing animals, things are changing rapidly and windows of opportunity can open and close very quickly. Here is my paper on malocclusions:

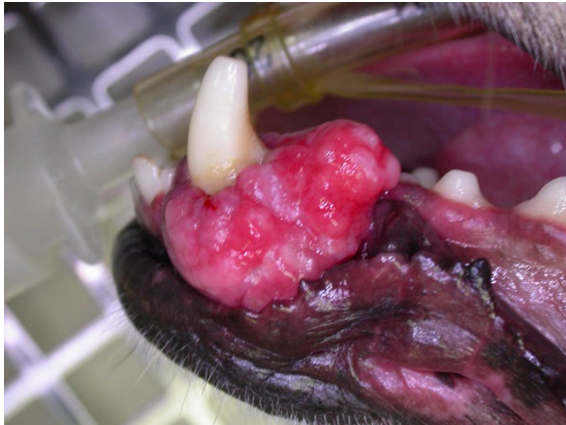www.toothvet.ca/PDFfiles/malocclusions.pdf.

So, as soon as you see an animal with a malocclusion, get some good photographs and send them to us. The last page of this paper shows some examples of good images for assessing occlusal relationships and the malocclusion paper is full of examples.

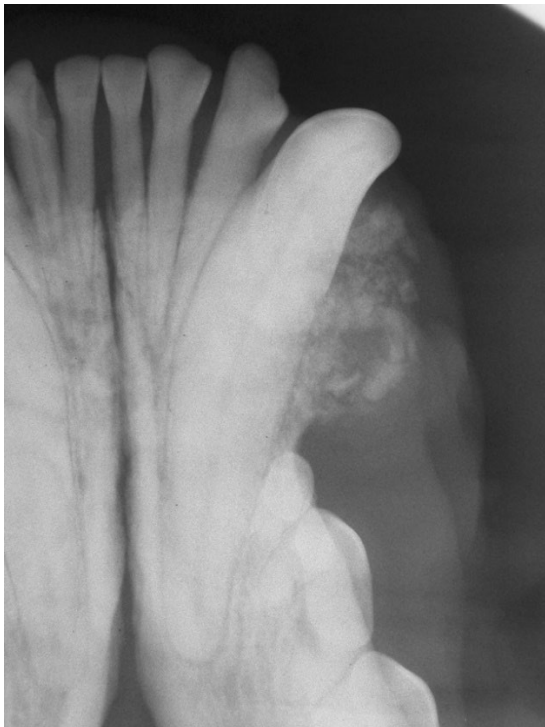Lumps and Bumps.

Anytime you see a swelling, lump, bump, growth, get photos. I want to know the shape, size, character and location of the lesion in question and a good photo is going to be so much more instructive than any attempts to describe the situation in words.

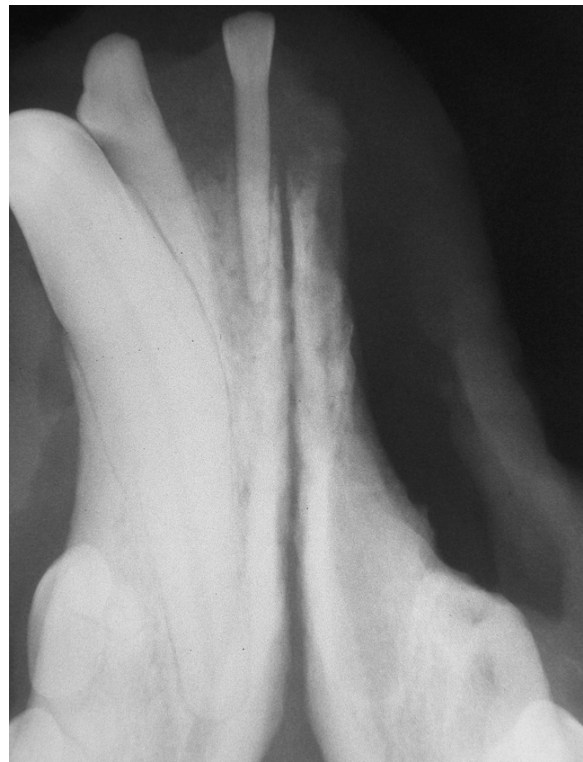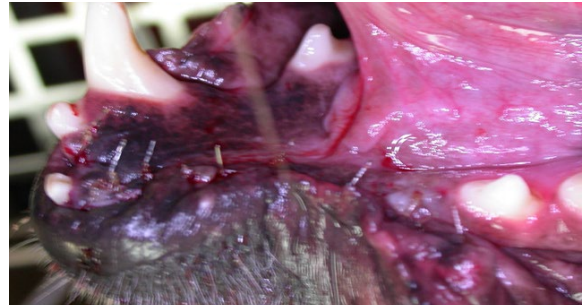
This photograph gives a good indication of the shape, size, location and character of the oral mass but gives no indication of bone involvement or depth of invasion.



This radiograph shows that the lesion is proliferative but there is no radiographic evidence of bone destruction or deep invasion (great news).



The mass was diagnosed as a peripheral odontogenic fibroma after excisional biopsy (curative-intent surgery) and just for fun, here are the post-op images.

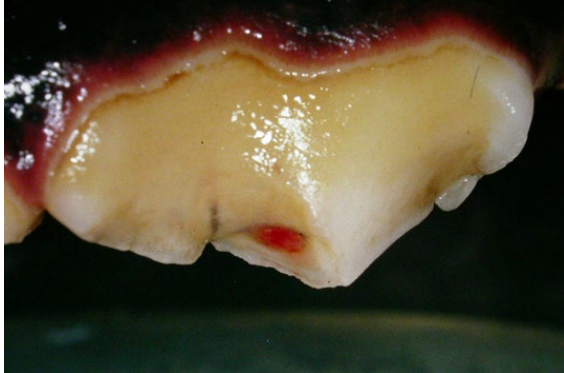


Coronal Damage.

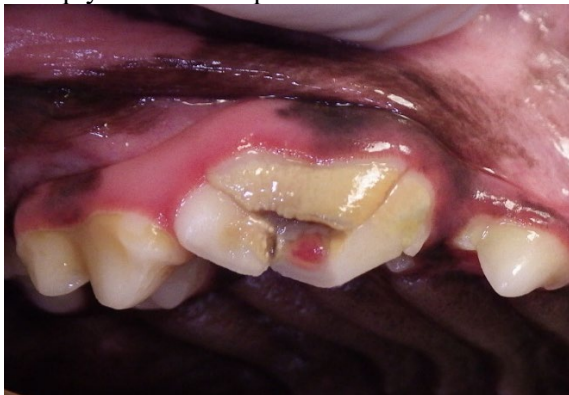Teeth may suffer abrasive wear and/or fractures. Good photos of the damage are sometimes of value in determining the degree of damage and how likely it is that the tooth may need treatment and what options might be available for consideration.

A picture like this (top of next page) tells me that the right upper 4th premolar tooth has a crown fracture with pulp exposure and the pulp is still vital. It also tells me that the damage is restricted to the crown of the tooth (does not go below the gum line). From this image I can say that the tooth

absolutely needs root canal treatment or extraction and deciding which would be based on many factors but at this stage, both options seem available to us.



In the next image, we see another right upper 4th premolar tooth with a fracture involving pulp exposure, but the damage obviously goes below the gum line because the slab defect is still attached. This tooth is very likely a “Humpty-Dumpty” and will require extraction.



8080

Never miss an opportunity to gather data.

For veterinarians, if you are finding things of interest while your patient is under anesthesia (being neutered; you doing a dental procedure) and you have something you want advice on, get photos AND intra-oral dental radiographs and send both. The more information I have to work with, the more helpful I can be.

And, if you think you will be referring the patient and have not already done so, grab blood for a CBC (with platelet count) and biochemical profile to send along with the referral form and images.

How to get images of a wiggly pup?

Fair question. Some dogs are disinclined to sit still and allow facial manipulation while you try to compose and focus the shot. One trick that might help you is to take your dog for a long walk, or run, or some fetch in the yard... Some activity that will tucker them out. Then, when they come in and lie down for a nap, you might find it easier to get the photos.

How to send us images:

It may seem I am asking you to follow a lot of rules here, but doing it right the first time takes far less time than having to do it over and over until you get it right.

The best way by far for you to send us images is as jpeg attachments to an email. If you have many large files, it is fine to send them a few at a time in multiple messages – just tell me how many images to expect so I will know if I have received all you intended for me.

Use the pet's first and last name (Scuffy Smith) as the subject line so it is easy to find and follow the thread of the ensuing back-and-forth messaging.

Please do **not** send the images embedded in the body of the email as it takes us much longer to pull them out and put them in a folder where I can view and manipulate them for better interpretation. Also, please avoid .zip and third-party cloud services (One Drive etc) as they sometimes limit my ability to retrieve, save and manipulate the images.

It is very important that you send the correct images. It may seem odd to have to say this, but on more than one occasion, I have been sent images that were clearly not from the animal we were taking about.

For radiographs, it would be great if you could orient them as shown in this example - www.toothvet.ca/PDFfiles/normal_canine_rads.pdf. But more important than if you have spun them around properly is to make sure that you get the right and left orientation correct. There are a number of clinics that consistently send me images that are mirror-image of how they should be (the images labelled as being of the right side appear as if they are the left side) and this can

certainly lead to errors in communication and interpretation. So please review how your radiographic images are appearing on the screen to ensure that they follow the conventions in that example and as outlined in this paper published in the Can Vet J - www.ncbi.nlm.nih.gov/pmc/articles/PMC5764209/.

If the images are coming from a veterinary facility (rather than the owner), they ought to be labelled (to follow CVO guidelines) with patient identification, clinic name, date etc. More on that here - www.toothvet.ca/PDFfiles/Radiograph_Labeling.pdf. While you are labelling your rads, it would be great to add the same information to the clinical photographs.

A few more thoughts about labelling:

- Position the text in a corner of the frame where it does not cover an important part of the image
- There needs to be enough information to identify patient, date and anatomic location but try to keep it to a minimum to avoid covering important parts of the image
- I use patient # on the images so I can figure out who it is by cross-referencing with my database but I can still share the image without violating client confidentiality.

Having dates on the images can be very important as you may be sending me images from several visits (tracking progress of a problem for instance), and I will need to know the time-line (which image was taken when, how much time between images...) to piece together the story the pictures are trying to tell me.

Photos of computer screens are not good:

When sending radiographs, please do not just photograph your computer screen and send that photo. Photographs of computer screens often yield low quality images making accurate interpretation more difficult (raising the risk of mis-interpretation). Whatever software you are

using, there has to be a means by which you can export your radiographic images as jpeg files for sharing. If you do not know how to do that, contact your software vendor or customer support and have them walk you through it.

Equipment:

The camera I am using currently is the Ricoh WG-60 (previously I was using their WG-III) Among the features I value with this little unit are:

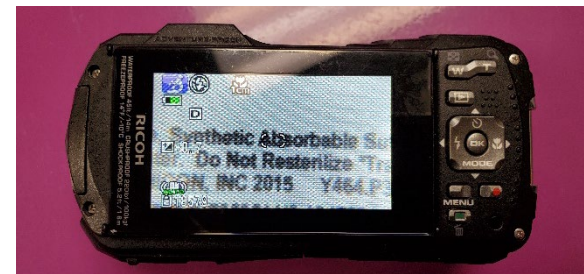
- it is water, dust and shock proof so we can wash/disinfect it between cases,
- there is an LED light array around the lens for well-lit close-up images,
- the viewing screen is quite large,
- the “digital microscope” allows me to get very close (less than 1 cm) and still get excellent focus and lighting.



Front of Camera.

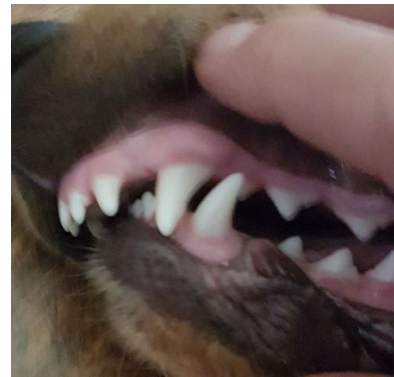
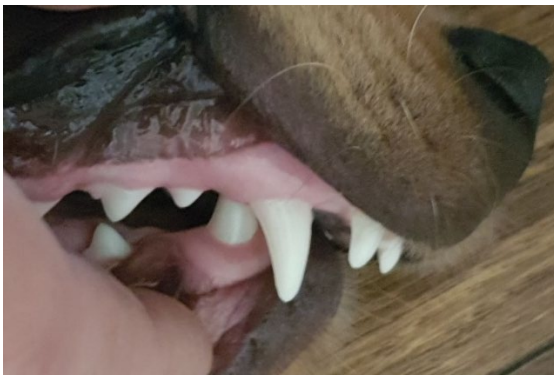
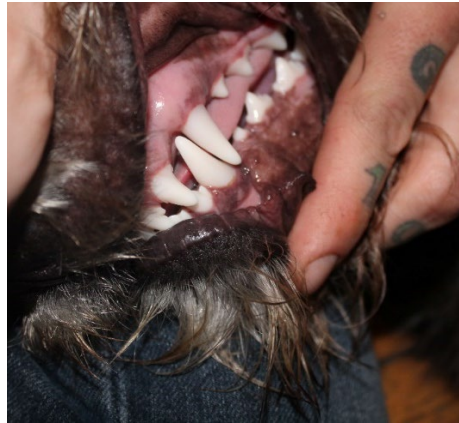
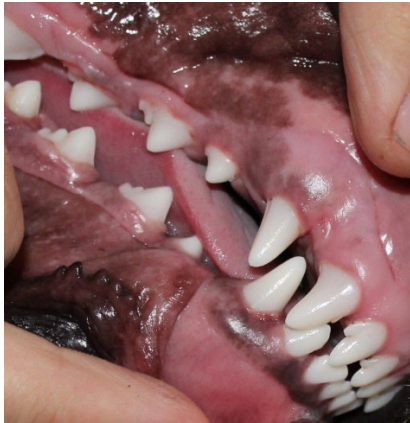
Camera lying on top of a pack of suture.

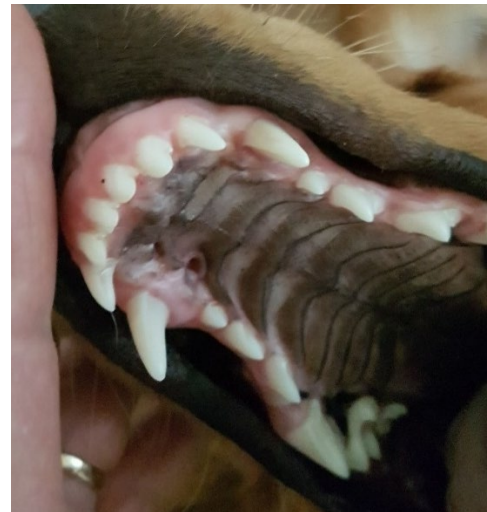
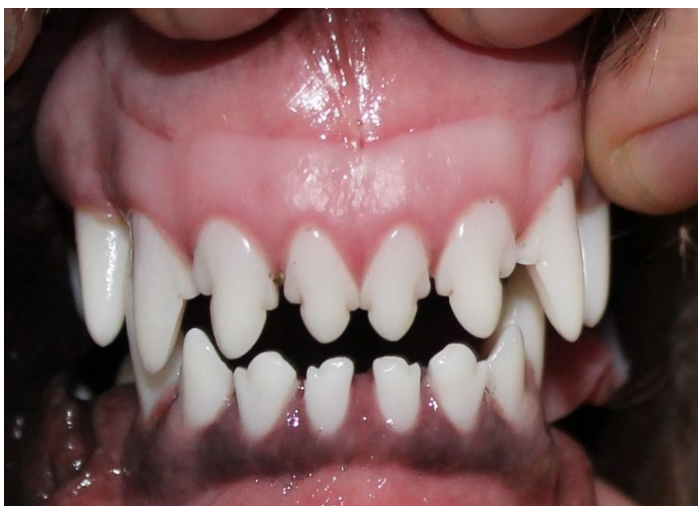

Resulting very “close-up” image.

Examples of the images we are usually looking for when dealing with malocclusions, in particular.



Mouth closed but lips retracted so I can see the teeth and the relationship of the upper and lower jaws and their teeth to each other



The first image is mouth closed but lips retracted so I can see the symmetry of upper and lower jaws and the second image is an open-mouth view of the palate (upper jaw) so I can see the traumatic pit being caused by a lower tooth.

Visit www.toothvet.ca/Old%20CUSP%20Articles.htm for many more illustrated articles.

Subscribe to my You Tube channel - www.youtube.com/channel/UCjX8caNAj6o4O8f4OrPbsBg.



SENDING IMAGES FOR TELE-MEDICINE

For Pet Owners:

Complete this form - http://www.toothvet.ca/PDFfiles/client_pat_info_fillable_2020.pdf, save it to your computer and send me a copy along with the images.

Use your pet's name and your last name as the subject line in the email (Scruffy Smith).

Include an explanation and timeline of the problem and your specific question.

See the examples in the preceding pages for guidance on what images I am looking for.

You may find it helpful to tucker you dog out with some vigorous activity and then when they flomp down for a nap, it might be easier to get useful images.

Send the images as jpeg attachment, not embedded in the body of the message.

For Veterinarians:

Complete this form - http://www.toothvet.ca/PDFfiles/referral_fillable_form.pdf, save it to your computer and send me a copy along with the images.

Use your pet's name and your client's last name as the subject line in the email (Scruffy Smith).

Include specific questions in the email.

See the examples in the preceding pages for guidance on what images I am looking for.

Send the images as jpeg attachment, not embedded in the body of the message.

If the animal is anesthetized, get photographs AND intra-oral dental radiographs and send both.

If you think you might be referring the case, be sure to get CBC, platelet count and biochem to send along with the images and referral form (www.toothvet.ca/PDFfiles/how_to_refer.pdf).

Make sure the images are properly labelled/oriented and really are of the animal in question.

Send the images as jpeg attachment, not embedded in the body of the message.

Do not send photographs of the computer screen – find out how to export the images as jpeg files.

For Both:

Send you emails to info@toothvet.ca unless instructed otherwise.

Read the preceding five pages for more information and guidance.