

## Chapter 20: Pathology

There are many pathologic conditions, which occur in and around the mouth. Some of them have already been discussed in Chapters 7, 13, 15, 16, 17, 18 and 19. This chapter will cover a few more conditions that did not fit in those other chapters. It is not a complete catalogue.

### Cavities/Caries

“Cavities” is the common term for dental decay, more properly known as *caries*, which is Latin for rottenness. Caries is one of the most common diseases in man. Caries has been defined as “*a disease of the calcified tissues of the teeth resulting from the action of micro-organisms on carbohydrates, characterized by decalcification of the inorganic portions of the tooth and accompanied or followed by disintegration of the organic portion*”.

Caries then, is a bacterial decay of the tooth structure brought about by the release of acids from oral bacteria fermenting carbohydrates on the tooth surface. Therefore, a diet high in highly refined and easily digestible carbohydrates will favor the development of caries. As western civilization progressed, our diet changed to include the types of foods that would promote decay and so caries became a widespread and serious concern. It is only recently that the use of fluoride and improved oral hygiene practices has brought about a decline in the incidence of caries.

Many owners are unaware that dogs are subject to caries. Though the incidence of caries in dogs is much lower than in humans, it can and does occur and we must watch for areas at risk and recommend such preventive treatments as are reasonable. In a review of my own records (published in the *Journal of Veterinary Dentistry*, Vol. 15, #2), I found that 5.25% of my adult canine patients had one or more caries lesion.

There must be several factors in place for caries to develop. They include:

- natural tooth structure with susceptible surface exposed to the oral environment
- complex indigenous microflora
- food ingested by mouth

There are many modifying factors as well, which influence the location of the lesion.

Among the reasons proposed for the lower incidence of caries in dogs are:

- conical tooth shape with less area for food impaction and stagnation
- diets which include little fermentable carbohydrate
- salivary pH is higher (in dogs, mean pH of 7.5 compared to 6.5 in humans) to buffer bacterial acids
- in dogs, a relatively low level of salivary amylase to breakdown starches which are retained in and around the teeth

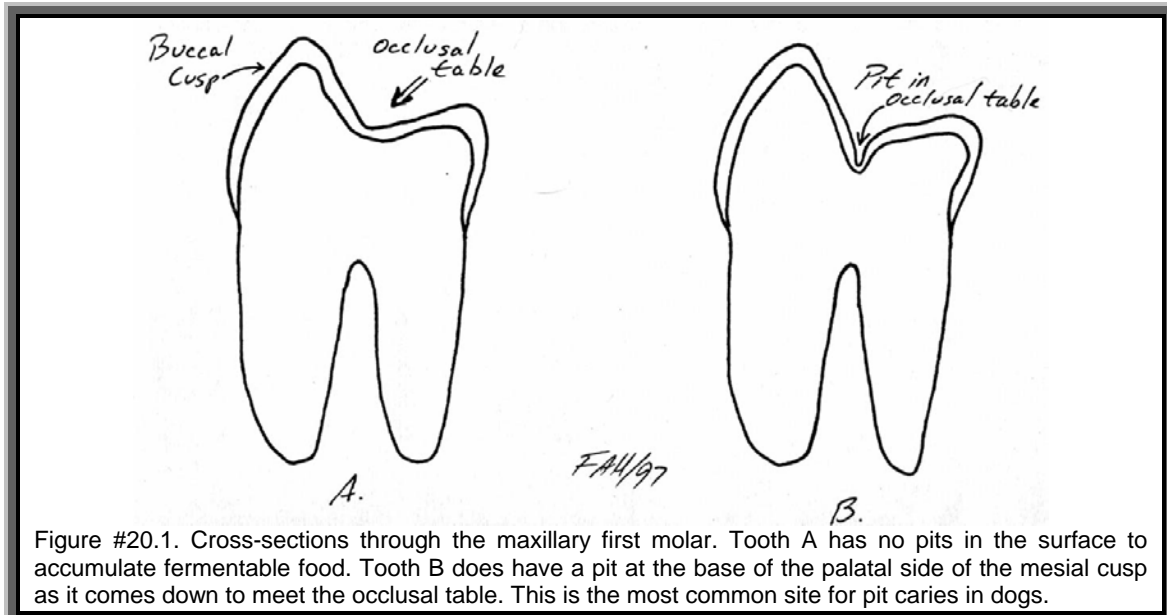
As bacteria on the tooth surface ferment the carbohydrates, acids (lactic, acetic, propionic) are released. These acids diffuse into and demineralize the surface enamel. Loss of mineral exposes the organic (protein) matrix of the enamel, which is digested by enzymes from the oral bacteria and/or leukocytes. As the process penetrates deeper, microcavitations develop under the surface. As these expand, they coalesce and the undermined enamel collapses.

There is a constant exchange of minerals between the enamel and the oral fluid. If this exchange is balanced, no lesion develops, but if there is a net loss of mineral from the enamel, caries develops. In the very early stages, before the protein matrix collapses, the process can be reversed and the lesion can ‘heal’. Once the protein matrix collapses, the lesion is irreversible and treatment is aimed at preventing further progression.

The rate of progression of caries depends more on factors external to the tooth such as the cariogenicity of microflora, the availability of acidogenic substrates and the remineralizing capability of oral fluids. Intrinsic factors include the degree of tissue mineralization and the amount of matrix protein.

Caries can be classified by location as pit and fissure caries, smooth surface caries or root surface caries.

In my experience, pit and fissure caries are the most common type in dogs. They can occur in the pits sometimes found on the occlusal tables



the maxillary molars. As Figure #20.1 shows, some teeth have a smooth transition from the palatal wall of the buccal cusps down on to the occlusal table. In other teeth, there is a pit at the base of the cusps and in these teeth, the enamel is thinner at the bottom of the pit. If food high in carbohydrates becomes trapped in this pit along with sufficient bacteria, a caries is very likely to develop.

Other locations at risk are the deep developmental grooves on the buccal surface of the maxillary fourth premolars and on the lingual side of the mandibular first molars between the mesial and central cusps. These grooves are often filled with calculus, but on deeper exploration, there may be soft, carious dentin at the base.

The series of diagrams in Figure #20.2 shows the progression of a pit caries. Initially, food becomes trapped in an occlusal pit. As the bacteria ferment the carbohydrates, acids diffuse into the enamel and start to remove minerals from the surface. The food packed in the pit prevents oral fluids from reaching the demineralized surface and so remineralization is not possible.

In time, the enamel is completely demineralized and the protein matrix digested. Now the caries has reached the dentin, which has a lower mineral content and a higher protein content. The decay progresses more rapidly in the dentin. Though the entrance to the lesions is the same size, the caries grows larger, undermining the overlying enamel.

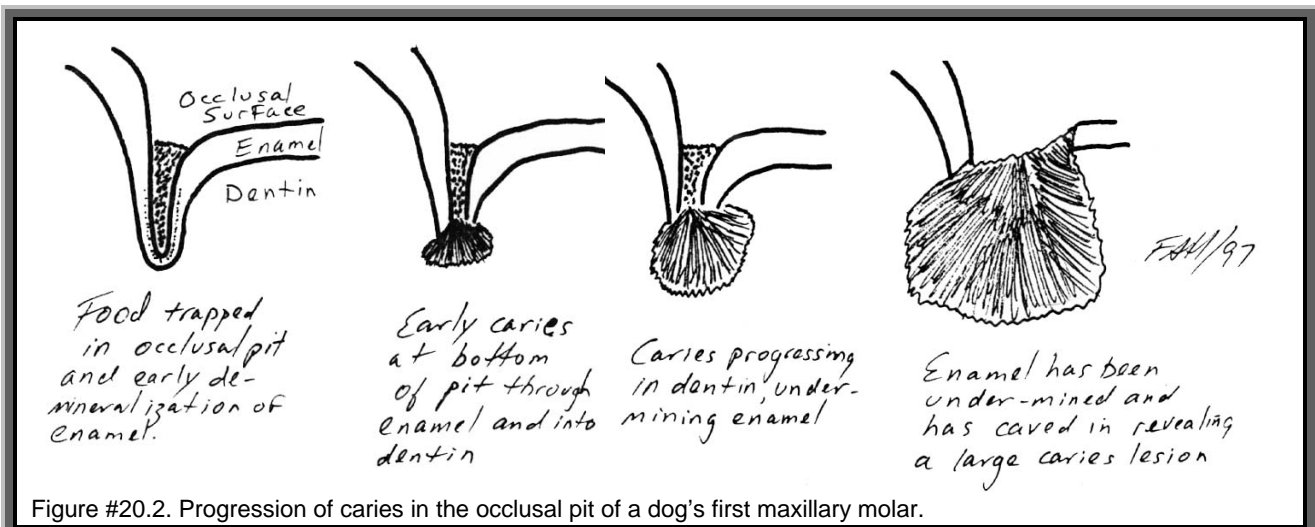


Figure #20.2. Progression of caries in the occlusal pit of a dog's first maxillary molar.

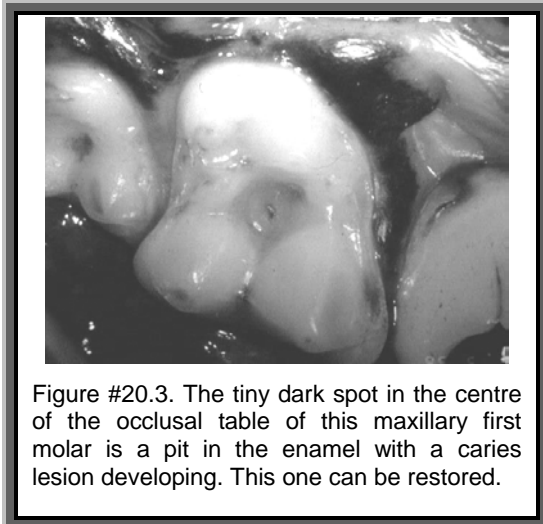


Figure #20.3. The tiny dark spot in the centre of the occlusal table of this maxillary first molar is a pit in the enamel with a caries lesion developing. This one can be restored.

Only when the caries is quite large does the overlying enamel cave in at which point the large caries becomes readily detectable. Unfortunately, by the time the lesion is large enough to be easily seen, it has usually extended into the endodontic system of the tooth and there is such extensive loss of tooth structure that extraction is the only option.

For teeth with deep occlusal pits in young animals that have not started to develop caries, the application of a Pit and Fissure Sealant is an effective preventive treatment.

For established caries, the decayed enamel and dentin and all debris are removed from the lesion. Endodontic therapy is performed if needed and then the prepared cavity is filled with a dental restorative of some type.

Whenever performing an oral exam or hygiene procedure, be on the look out for small caries lesions that are still treatable as well as areas that might be particularly prone to caries development.

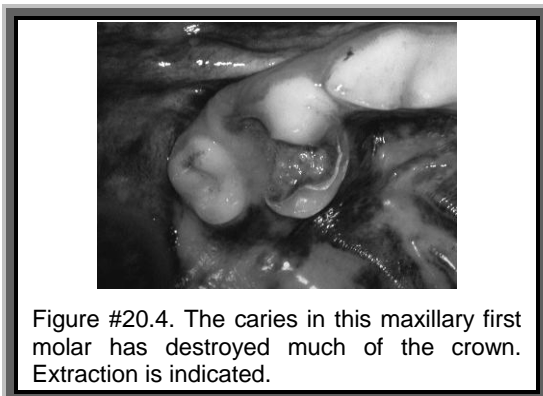


Figure #20.4. The caries in this maxillary first molar has destroyed much of the crown. Extraction is indicated.

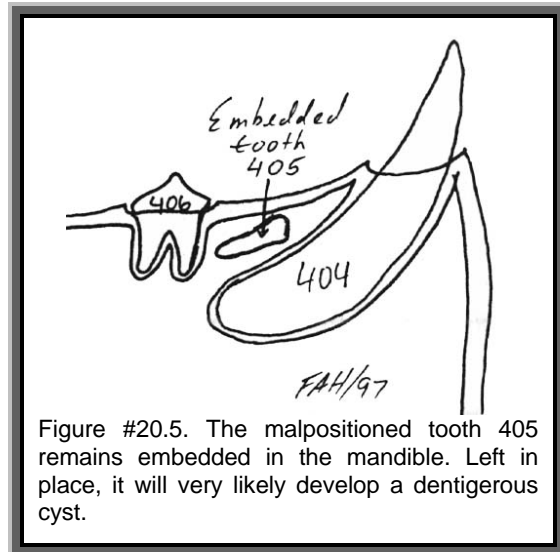


Figure #20.5. The malpositioned tooth 405 remains embedded in the mandible. Left in place, it will very likely develop a dentigerous cyst.

In examining the teeth with your dental explorer, check for pits and fissures. If a caries has started to develop, you will be able to force the tip of the explorer into the decaying surface. As you withdraw the instrument, the tip will stick and then let go, resulting in a metallic “ping” from the explorer tip. Sound enamel and dentin are too hard to allow the explorer to penetrate so if you can get your instrument to sink in at all, you have found a caries.

More advanced caries are usually filled with a foul smelling, soft material the consistency of cottage cheese. Under this is decaying dentin, which is softer than sound dentin. Under that, hopefully, will be some sound dentin covering the pulp of the tooth and upon which a restorative can be placed.

### Unerupted Teeth / Dentigerous Cysts

This condition was also mentioned in Chapter 16 and Figures #16.10 and #16.11 on pages 129 and 130 are worth reviewing.

In general practice, it is not uncommon to see an animal with missing teeth. Sometimes, the explanation is that they have been extracted previously or just never developed. Other times, the teeth are there, but are unerupted.

There are two types of unerupted teeth. Impacted teeth have had their eruption path blocked by some other structure, usually another tooth. This can occur when the jaw is too small for all the permanent teeth to fit properly and so one or more teeth get trapped within the jawbone.

The second type of unerupted tooth is known as an embedded tooth. In this case, there are no mechanical impediments to the eruption of the tooth, but it has remained unerupted anyway. This may occur if the tooth bud is pointing in the wrong direction so that the tooth grows nearly parallel to the jawbone instead of perpendicular to it.

A misdirected tooth could be the result of local trauma during development or due to iatrogenic trauma during extraction of deciduous teeth. Tooth bud positioning is generally considered to be under genetic control so this condition may well be inherited.

Some sources use the term “impacted tooth” for any type of unerupted tooth.

Whatever the cause for an unerupted tooth, it can be a serious matter. As the tooth is developing within the bones of the jaw, the crown is surrounded by a sac of epithelial tissue. Once the tooth breaks through the gingiva, the epithelium over the crown is lost. If the tooth never does break through, the epithelial sac remains around the unerupted crown. In time, this sac may start to produce fluid leading to the development of a dentigerous cyst. These cysts are considered to be benign tumors of dental origin, which are aggressively locally invasive. As they grow, they cause destruction of the surrounding alveolar bone. This destruction can extend to the supporting bone of adjacent teeth.

By way of example, a 3.5-year-old Shih Tzu was presented because the owner had noticed mobility in one of the mandibular incisors. Examination revealed the absence of the left central incisor (301), a mobile left intermediate incisor (302) and a solid left lateral incisor (303). All the right mandibular incisors were present and non-mobile. There was considerable movement between the two hemi-mandibles indicating mandibular symphyseal non-union.

A radiograph of the rostral mandible revealed the cause of the mobility of 302. Tooth 301 was developed to its full size but was impacted at the apex of the root of 302. A dentigerous cyst had formed around impacted 301 and the cyst had caused the destruction of all the bone supporting 302 as well as one wall of the alveolus of 303 and portions of the alveolus of the left mandibular canine (304). In a mandible that measured 18 mm from canine to canine, the cyst was 9 mm in diameter.

The owner of this dog had really wanted to salvage the loose intermediate incisor, but, in order to remove the impacted tooth and the wall of the cyst, the intermediate incisor, which had no bone support, had to be sacrificed.

My next patient that day was the 2.5-year-old son of the dog just discussed. He turned out to have both central mandibular incisors impacted as well as retained first right and left mandibular deciduous premolars and embedded first right and left mandibular permanent premolars. Around each unerupted tooth was a dentigerous cyst, the largest being around the right premolar. Surgery was performed at three sites in this tiny jaw to remove the offending teeth as well as one incisor that had become involved in a large cyst.

Dentigerous cysts will often present as a flocculent swelling along the gingiva in an edentulous area. There may or may not be a draining tract. Aspiration reveals an acellular, serous fluid or a serosanguinous fluid in the case of a traumatic aspiration.

Radiology is the key to diagnosing a dentigerous cyst and ruling out other causes of oral swelling. On the film, you will see an area of bone loss and a lucent halo surrounding the crown of an unerupted tooth. The tooth may be normal in appearance or malformed but should be recognizable as a tooth.

The treatment for dentigerous cyst is surgical removal of the unerupted tooth and curettage to remove the cyst wall. The defect can then be filled with a surgical packing material that supports bone healing or left to fill with blood prior to suturing the site with fine, absorbable material.

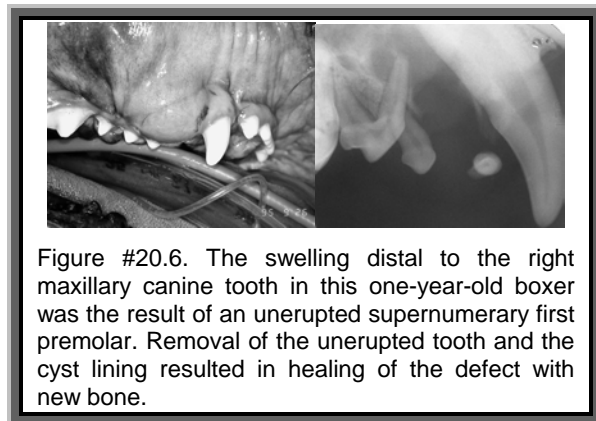


Figure #20.6. The swelling distal to the right maxillary canine tooth in this one-year-old boxer was the result of an unerupted supernumerary first premolar. Removal of the unerupted tooth and the cyst lining resulted in healing of the defect with new bone.

The moral of the story is, *if you find that a patient is missing a tooth and there is no history to confirm that it had been extracted, you should consider the likelihood of an unerupted tooth.*

A good time to check for unerupted teeth would be at spay/neuter. The animal will be anesthetized allowing for a very thorough oral examination. By six months of age, most animals should have all permanent teeth erupted so a missing tooth at this stage indicates the need for a radiograph. The radiograph should be made using intra-oral dental film, but can also be done with regular film using an open-mouth, lateral oblique projection. A straight lateral or ventrodorsal view will be of no diagnostic value as there will be too many superimposed structures to allow interpretation.

If the radiograph reveals an unerupted tooth, you must recommend its removal. Adopting a "wait and see" approach to missing or unerupted teeth will often allow significant bone destruction and increased tooth loss before the need for treatment becomes grossly obvious.

The temptation would be to perform the oral surgery at the same time as spay/neuter. The surgeon is cautioned against this. No oral surgery is ever sterile and the risk of post-operative infection at the spay/neuter site is significantly increased if this sterile procedure is done at the same time as any other non-sterile procedure. It may be better medicine to continue with the spay/neuter and have the animal return in a month or two for the oral surgery. This also allows time for the possibility of delayed eruption to occur. As a rule, I would not let an animal go past its first birthday with an unerupted tooth in place.

On the other hand, an argument can be made for doing the extraction while the animal is on the table. It avoids a second anesthetic and the possibility of the owner neglecting to come back for the oral surgery before a cyst develops.

Combining the procedures increases the risk of complication but delaying the extraction risks giving time for a cyst to develop and cause local problems. It is a judgment call. The anticipated ease of extraction and the state of oral hygiene should factor in the decision.

## Under-Erupted Teeth / Pericoronitis

Another abnormality that can be seen is an under-erupted tooth. In this case, the tooth erupts far enough to break through the gingiva, but a significant portion of the crown remains sub-gingival. Since the periodontal ligament and gingival attachments will not attach to the enamel of the crown, this leads to a pre-formed periodontal pocket. Food, debris and bacteria accumulate in this pocket and a pericoronitis (inflammation around the crown) ensues.

In Figure #20.7, the teeth at left and right have erupted properly. The gingival margin extends above the cemento-enamel junction by a millimeter but the attached gingiva is attached to the cementum above the bone level and the periodontal ligament is attached to the cementum within the alveolus.

The tooth at in the centre has erupted enough to break through the gingiva, but much of the crown remains embedded in the bone. The gingiva attaches to the bone, but there is a space between the bone and the enamel of the unerupted portion of the crown. This space will quickly become contaminated and infected. The under-erupted tooth needs treatment of some sort. There may be a few options but in most cases, extraction would be indicated.

For significant teeth that are just slightly under-erupted, a periodontal surgery known as crown lengthening can be performed to expose more of the crown and preserve the tooth.

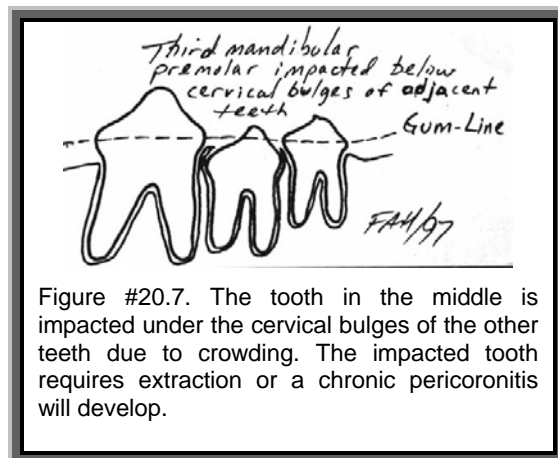


Figure #20.7. The tooth in the middle is impacted under the cervical bulges of the other teeth due to crowding. The impacted tooth requires extraction or a chronic pericoronitis will develop.

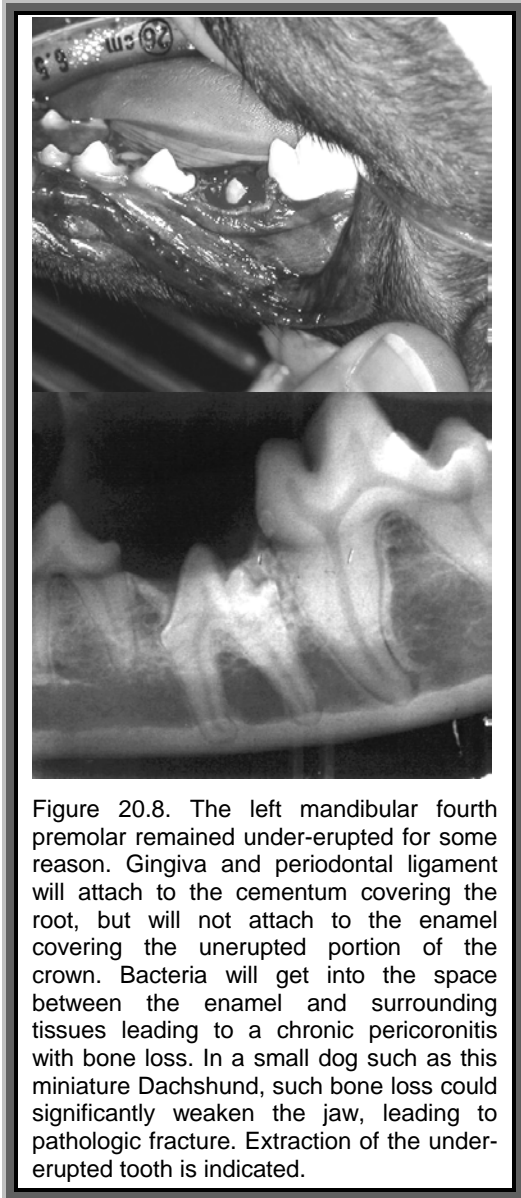


Figure 20.8. The left mandibular fourth premolar remained under-erupted for some reason. Gingiva and periodontal ligament will attach to the cementum covering the root, but will not attach to the enamel covering the unerupted portion of the crown. Bacteria will get into the space between the enamel and surrounding tissues leading to a chronic pericoronitis with bone loss. In a small dog such as this miniature Dachshund, such bone loss could significantly weaken the jaw, leading to pathologic fracture. Extraction of the under-erupted tooth is indicated.

## Dental Deformities

The permanent teeth may be afflicted with a variety of deformities. Some are caused by external factors while others may be congenital. Some deformities are of little significance, others require management but can be treated and others require extraction.

### Enamel Defects:

The enamel forms early in the development of the tooth and is produced by a layer of cells known as ameloblasts. These cells line the inner enamel epithelium, which is the innermost layer of the sac of tissue surrounding the developing crown. If anything upsets the ameloblasts during enamel development, then the enamel being

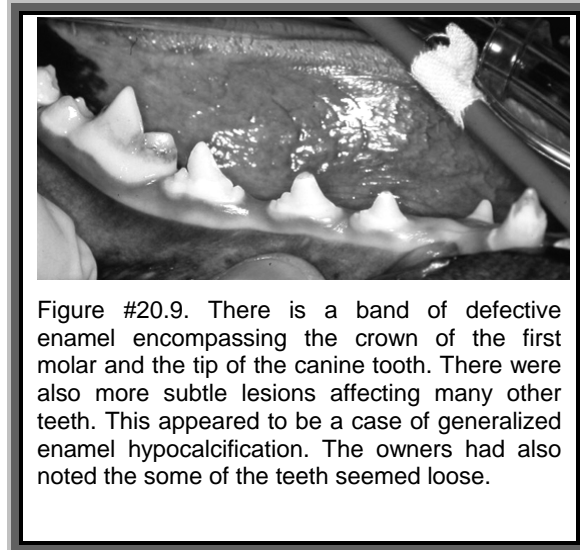


Figure #20.9. There is a band of defective enamel encompassing the crown of the first molar and the tip of the canine tooth. There were also more subtle lesions affecting many other teeth. This appeared to be a case of generalized enamel hypocalcification. The owners had also noted the some of the teeth seemed loose.

formed at that time or in the location of the disruption will be defective. The enamel produced prior to and following the insult may be normal and so when the cause is a generalized disruption of ameloblastic activity, there is a band of defective enamel circling the crowns of the teeth.

There are two distinct forms of developmental enamel defects.

In *enamel hypoplasia*, there are areas on the crown(s) where the enamel is thinner than normal. The enamel present is as hard and shiny as the surrounding normal enamel but there is a terraced or stair-step appearance to the crown.

In *enamel hypocalcification* the enamel may be a normal thickness at eruption, but is poorly mineralized. This soft enamel quickly takes up stain and flakes away, leaving an area of exposed dentin surrounded by darkly stained enamel.

Some enamel defects are uncomplicated while others may be associated with disruption of other dental tissues.

Evaluation of enamel defects should include radiographs to assess root and endodontic status. The dog in Figures #20.9 and #20.10 had generalized enamel hypocalcification as well as generalized root dysplasia.

If the root structure is sound and there is no evidence of endodontic disease, the restorative treatment is indicated to replace the missing enamel, to create a smooth coronal contour to seal the exposed dentin and protect the underlying pulp. In cases of generalized

hypocalcification, this can be a very large undertaking, as many teeth will need attention.

Treatment begins with debridement of the lesion to remove defective enamel from the margins and create a clean dentin surface. Then a composite restorative is bonded onto the dentin and polished smooth. For very shallow lesions, treatment may be restricted to simply coating the exposed dentin and enamel margins with a fluoride-releasing dentin bonding agent to seal the dentin tubules.

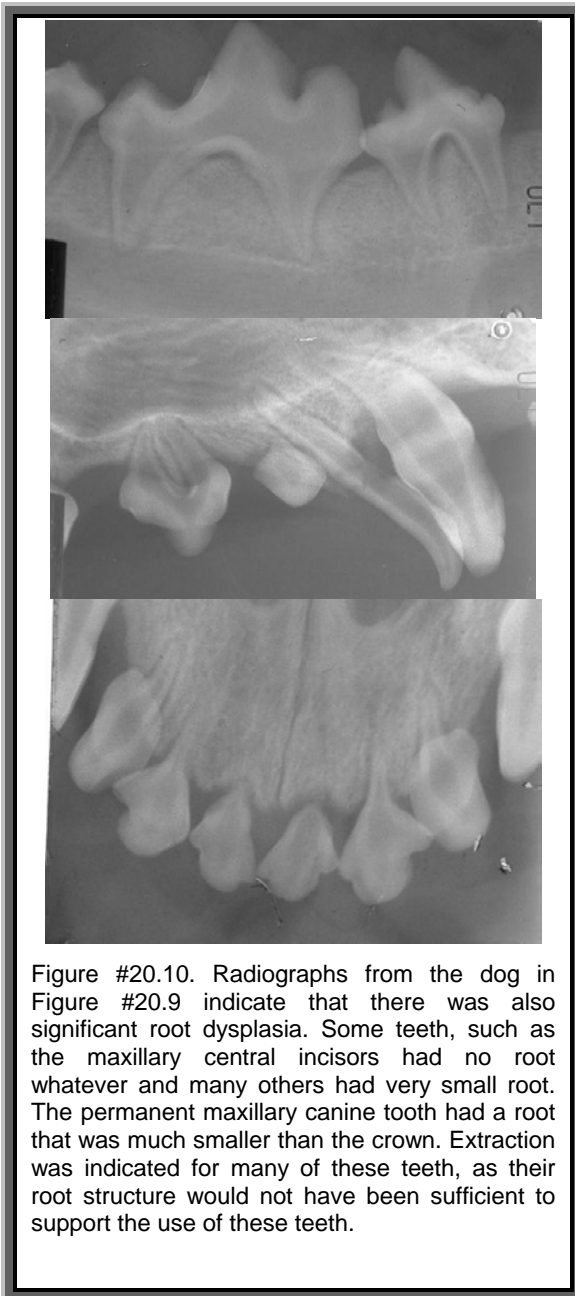


Figure #20.10. Radiographs from the dog in Figure #20.9 indicate that there was also significant root dysplasia. Some teeth, such as the maxillary central incisors had no root whatever and many others had very small root. The permanent maxillary canine tooth had a root that was much smaller than the crown. Extraction was indicated for many of these teeth, as their root structure would not have been sufficient to support the use of these teeth.

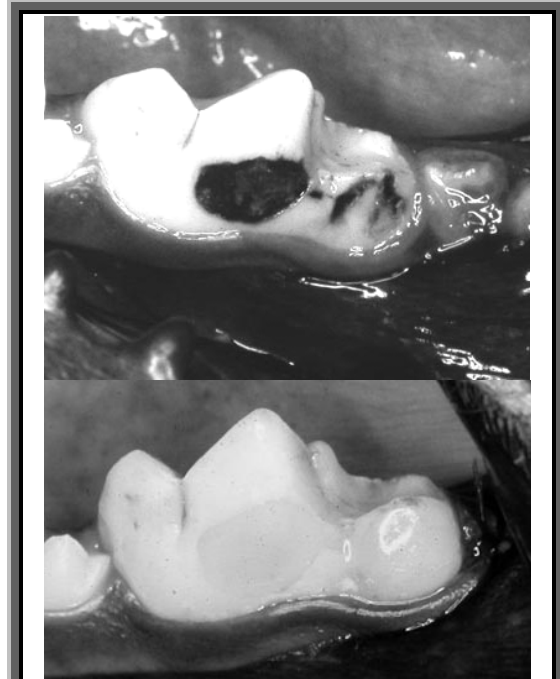

Figure #20.11. This left mandibular first molar was damaged during development when the pup was bitten in the head. There were large areas of enamel hypocalcification and enamel loss by the time of presentation. Further defective enamel was removed, the exposed dentin cleaned and a bonded composite restoration placed to replace the missing enamel. The result is a clean, smooth crown and sealed dentin tubules.

Care should be taken when cleaning the teeth of affected animals, as it will be possible to remove the restoratives when using an ultra-sonic scaler.

#### Dens in Dente:

Latin for “tooth in tooth” this condition is a developmental abnormality that sees the developing tooth fold in on itself. As a result there appears to be a second tooth residing within the pulp chamber of a larger tooth. There is often a direct communication from the surface of the tooth to the pulp chamber and the presence of the “inner tooth” makes endodontic treatment impossible. Treatment is extraction.

#### Gemini Teeth:

When a permanent tooth is forming it may attempt to splint into two teeth. If this separation is complete a supernumerary tooth is seen. If the separation is incomplete, a gemini tooth is formed. These teeth typically have a longitudinal split in the crown or what may appear as two

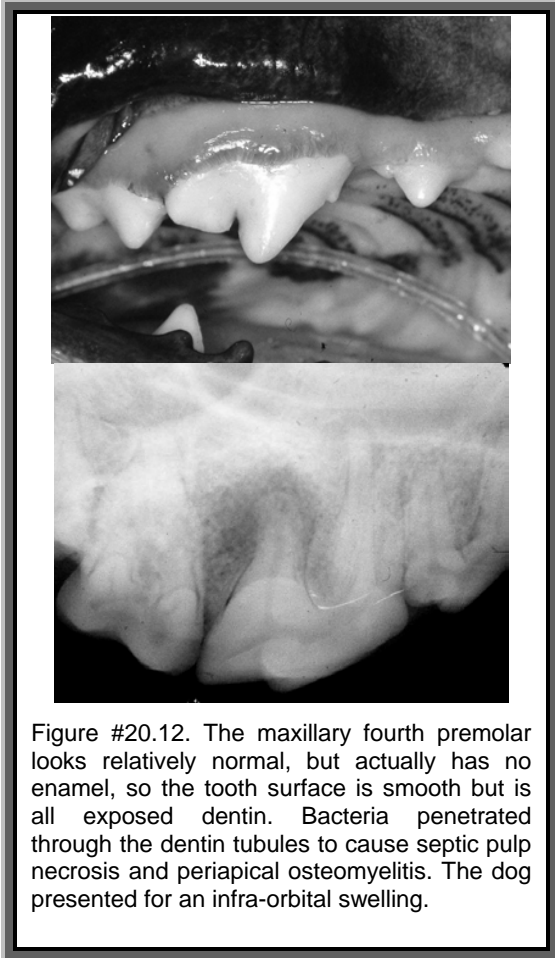


Figure #20.12. The maxillary fourth premolar looks relatively normal, but actually has no enamel, so the tooth surface is smooth but is all exposed dentin. Bacteria penetrated through the dentin tubules to cause septic pulp necrosis and periapical osteomyelitis. The dog presented for an infra-orbital swelling.

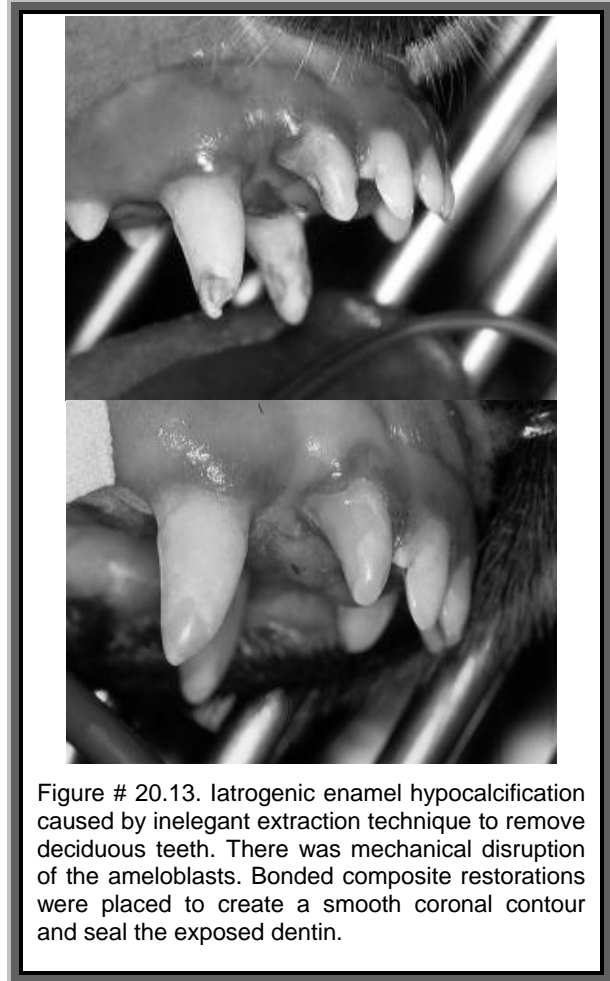

Figure # 20.13. Iatrogenic enamel hypocalcification caused by inelegant extraction technique to remove deciduous teeth. There was mechanical disruption of the ameloblasts. Bonded composite restorations were placed to create a smooth coronal contour and seal the exposed dentin.

crowns attached to a single root all with a single pulp chamber. If there is no communication from the tooth surface into the pulp chamber, then a bonded restoration to fill the split is indicated. This prevents entrapment of debris between the crown segments.

#### Non-Specific Deformities:

Other deformities include idopathic and iatrogenic dilacerations (bending) of roots and crowns and abnormal openings into the pulp chamber. Then some teeth are so badly deformed, it is hard to put a label on them.

For many of these teeth, extraction is the only option and often the need is readily apparent, as the gross deformity is easy to see. For others the deformity may be more subtle and the need for treatment harder to detect. One must be ever vigilant in examining the oral cavity to look for subtle indicators of disease and then to investigate these aggressively (and radiographically of course).

## Dental Cysts

As well as dentigerous cysts forming around unerupted teeth, there are a number of other dental cysts that can form. Usually, the cyst is named by its location. Therefore, a cyst at the root apex is an apical cyst. A cyst along the side of the root may be referred to as a lateral periodontal cysts. These cysts may contain fluid or semi-solid material.

Apical and periodontal cysts may be caused by chronic irritation of endodontic or periodontal origin or may be idopathic.

Depending on their location and the degree of damage to surrounding structures, these cysts might be treated by curettage. If the cause is endodontic, then root canal treatment would also be necessary. In most cases, by the time the lesion is detected, there is so much damage to surrounding structures that extraction is indicated.

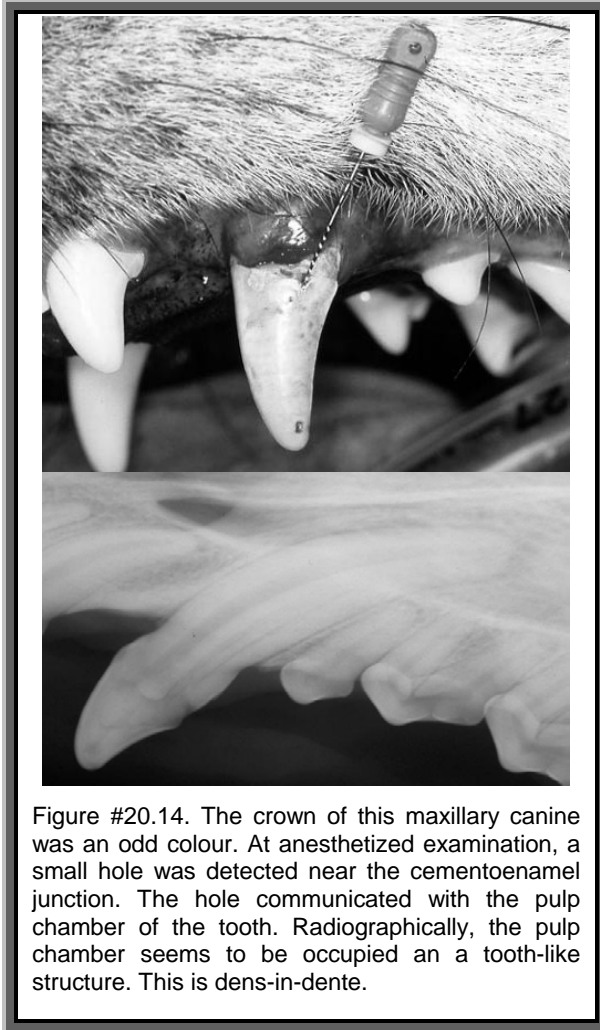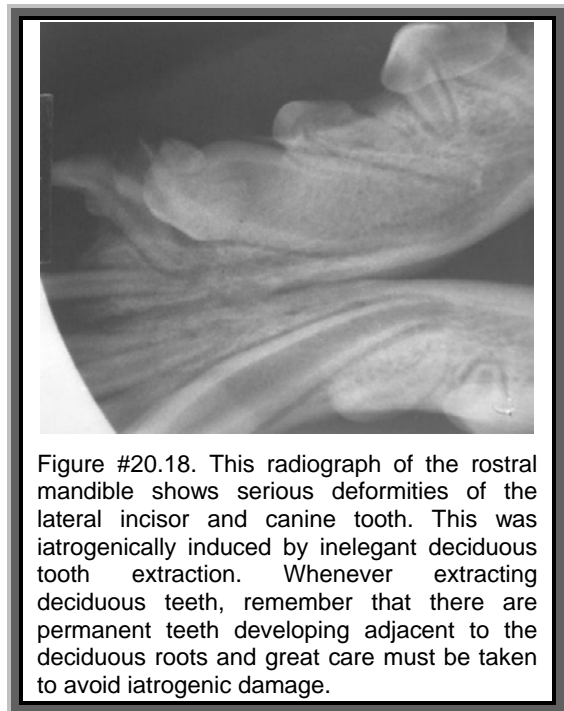
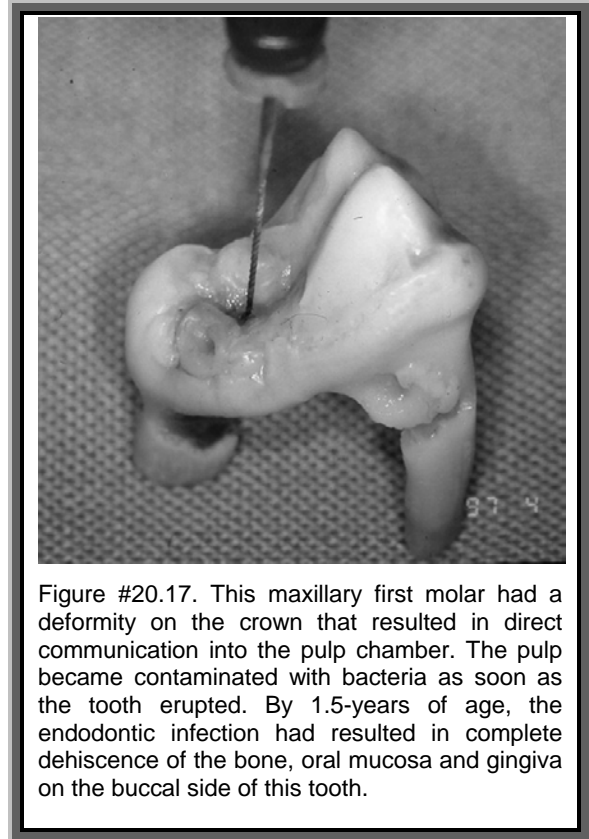
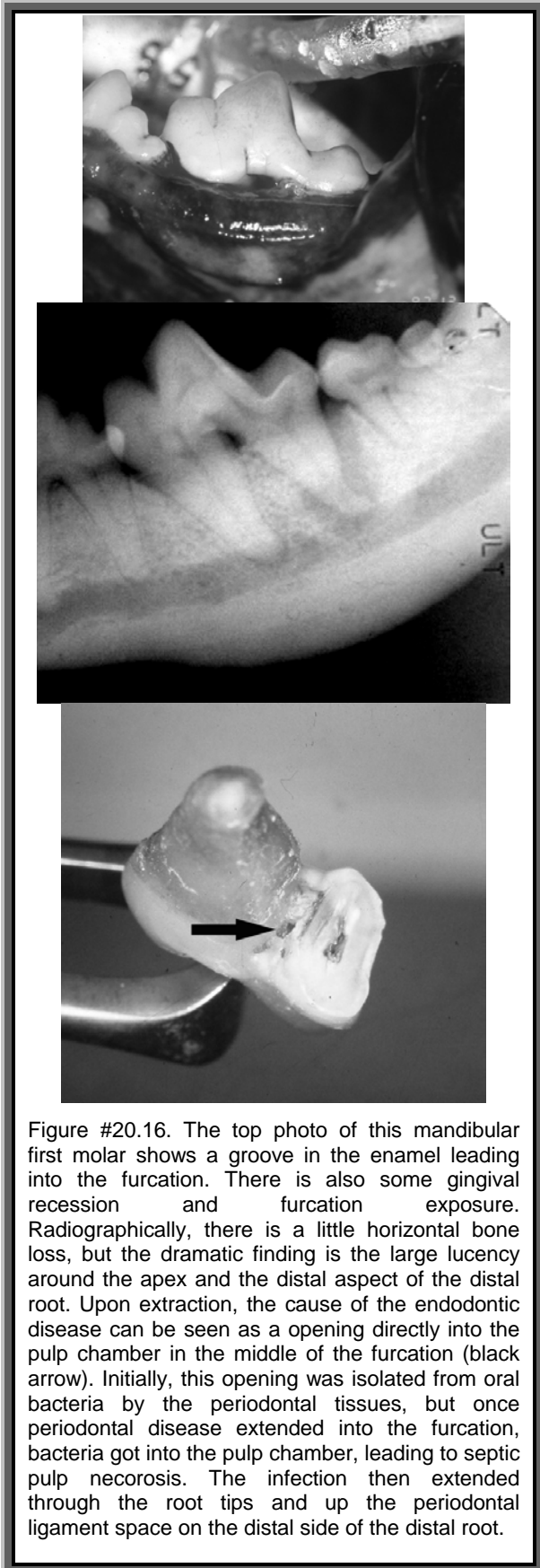




Figure #20.14. The crown of this maxillary canine was an odd colour. At anesthetized examination, a small hole was detected near the cemento-enamel junction. The hole communicated with the pulp chamber of the tooth. Radiographically, the pulp chamber seems to be occupied an a tooth-like structure. This is dens-in-dente.

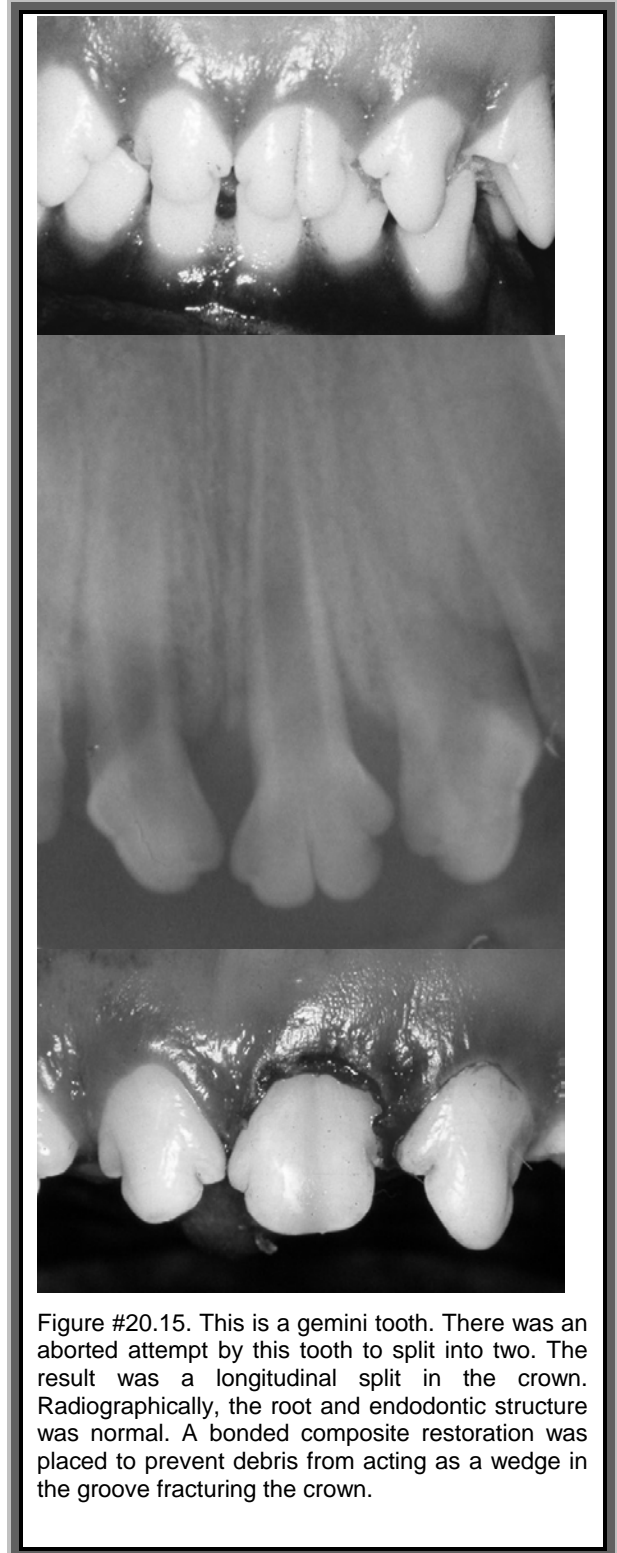

Figure #20.15. This is a gemini tooth. There was an aborted attempt by this tooth to split into two. The result was a longitudinal split in the crown. Radiographically, the root and endodontic structure was normal. A bonded composite restoration was placed to prevent debris from acting as a wedge in the groove fracturing the crown.



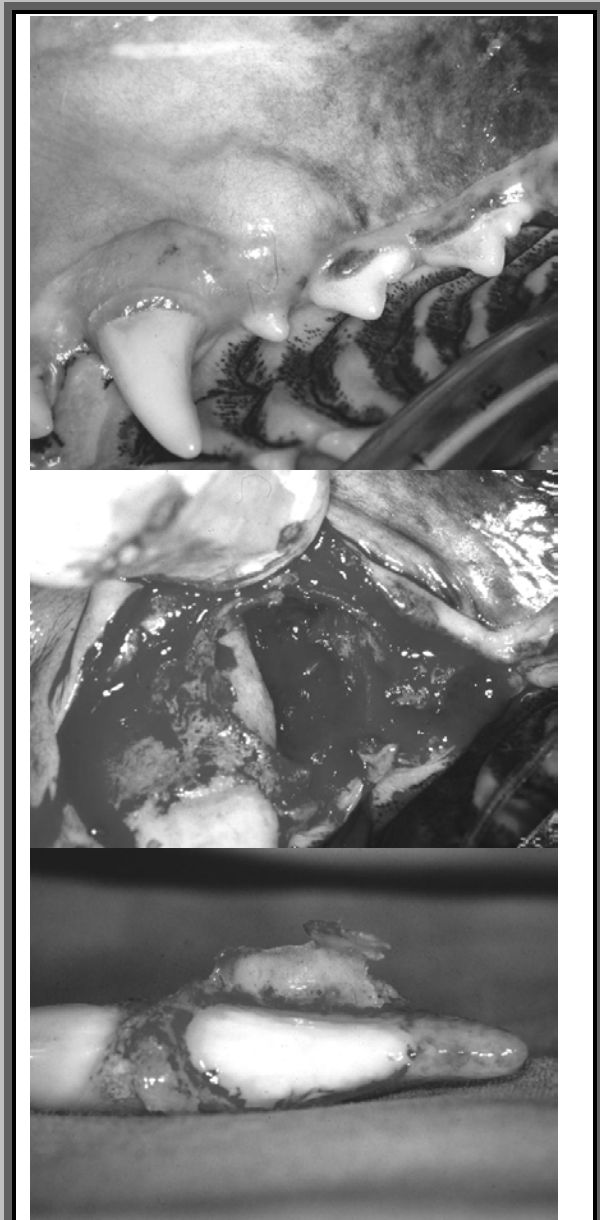


Figure # 20.19. A lateral periodontal cyst of the left upper canine tooth. Unfortunately, by the time the lesion was detected, there was significant loss of periodontal support for the tooth and extraction was indicated.