

Chapter 15: Endodontics

Endodontics is that branch of dentistry that deals with the internal anatomy of the tooth and the area where the inside of the tooth communicates with the rest of the body.

Teeth are composed of four main tissues. The crown is covered by a thin veneer of enamel and the root is covered by a thin layer of cementum. Under the enamel and cementum is dentin and inside the dentin is a chamber filled with soft tissues known collectively as the dental pulp. The chamber within the crown is called the pulp chamber and within the root it is called the root canal.

The pulp is a highly organized collection of tissues that includes blood vessels, nerves, lymphatic channels, undifferentiated cells and highly specialized cells (it gets a forty-page chapter in Orban's Oral Histology and Embryology). The pulp can become diseased in a number of ways, but they all boil down to inflammation (usually due to infection) or avascular necrosis (usually due to trauma).

Endodontic Anatomy & Physiology

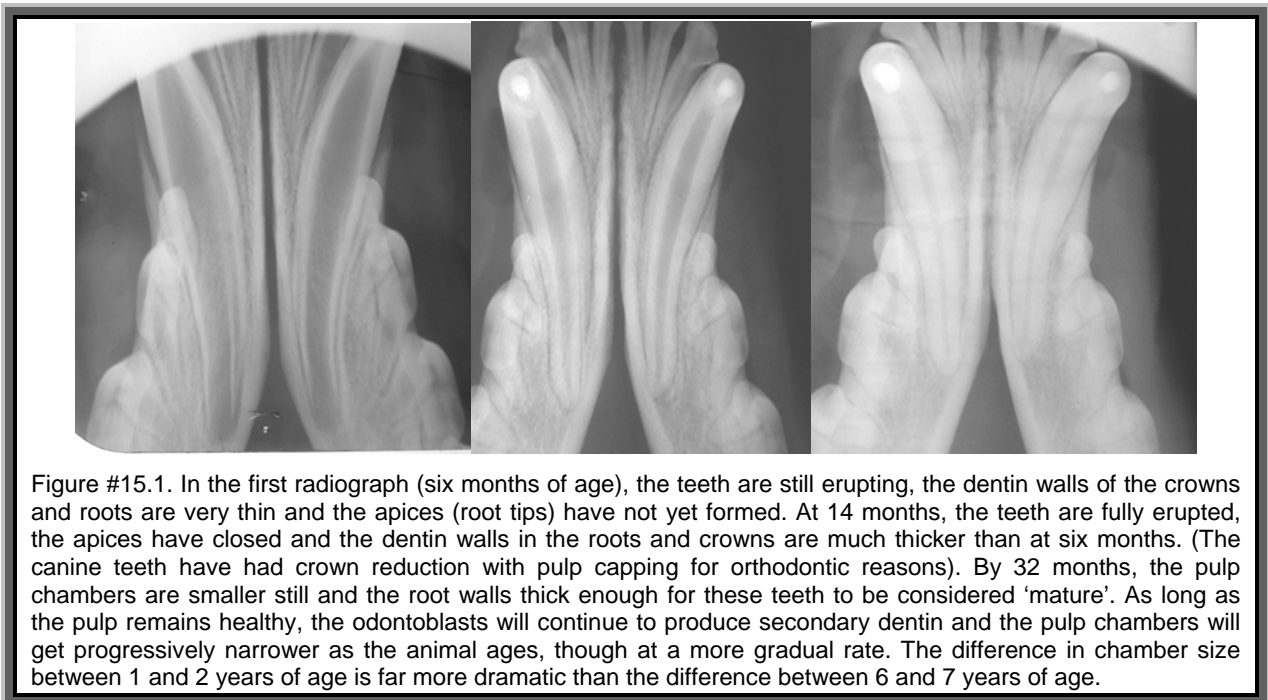
When a permanent tooth is developing within the jaw of a young animal, it is constructed from the outside in. That is to say, the enamel of the crown is produced early in the process so that the

outside dimension of the crown is established early. Once the enamel is formed, the tissue that made it goes dormant and no more enamel can ever be produced for that tooth.

Inside the tooth is the pulp. Lining the inside wall of the developing tooth is a single layer of low columnar cells known as *odontoblasts*. These cells produce the dentin. During pre-eruptive development and during eruption, the odontoblasts produce *primary dentin*. Once the tooth has developed to its final length, the odontoblasts produce *secondary dentin* such that the pulp chamber inside the tooth gets smaller as the wall of the tooth gets thicker. This progression can be seen in the series of radiographs in Figure #15.1. Also review Figures #7.4 to #7.8 on pages 27 to 29.

There is another form of dentin known as *tertiary, reparative or irregular dentin*. If there is a chronic but low-grade stimulation of the odontoblasts, they may respond by producing dentin at an accelerated rate. This is an attempt to create a thicker buffer zone between the pulp and the noxious stimulus. Once the pulp has retreated sufficiently from the stimulus, tertiary dentin production ceases. The tertiary dentin is structurally less organized than primary and secondary dentin and has a much darker colour.

In dogs and cats, after the apex is 'closed', there



are still several tiny channels through which the pulp communicates with the rest of the body. This collection of channels constitutes the apical delta (Figure #7.8, page 29 and figure #15.2 below). This is the only way into or out of the tooth – there is no collateral circulation.

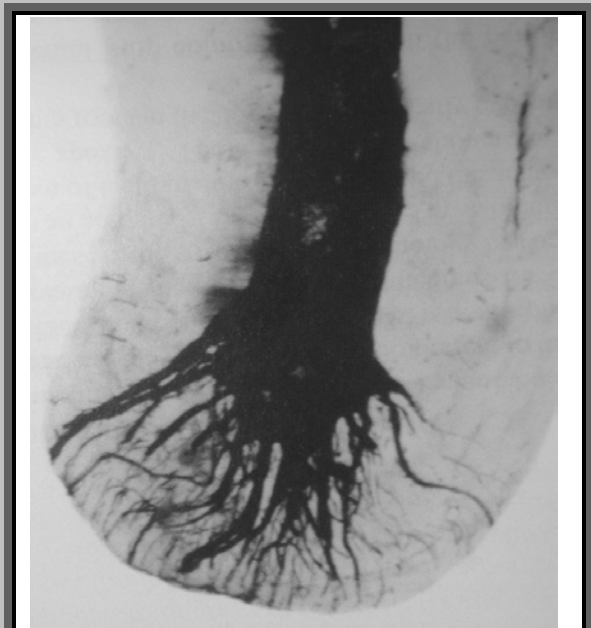


Figure #15.2. The apical root canal and dental stained with India ink in a decalcified root. There may be delta channels anywhere in the apical third of the root and occasionally lateral accessory canals anywhere on the root surface.

Dentin is porous. This is a crucial point to keep in mind as it has great impact on the effects of various dental injuries on the pulp.

The photo-micrograph (Figure #7.5, page 28) shows a clean, freshly cut dentin surface. In human teeth, each mm^2 of freshly cut dentin has ~40,000 open pores. These pores are the hollow lumens of the *dentin tubules*, which make up the bulk of the dentin. Ultrastructurally, the dentin is made of a collection of hollow tubules packed tightly together with *intertubular dentin* filling the spaces between the tubules.

Another point that is very important to understand is the intimate relationship between the odontoblasts and pulpal nerve fibers and the dentin tubules. There are cytoplasmic extensions of the odontoblasts that run through the dentin tubules to the dentin-enamel or dentin-cementum junction. There are also nerve fibers lying alongside the *odontoblastic processes* within the

Studies published in 1992 concluded that dogs and cats feel pain just like we do. They behave differently than we do – they do not complain. They just carry on because they have no alternative.

tubules (Figure #7.4, page 27). I want you to keep this relationship in mind, as it is key to understanding a number of endodontic concepts.

The nerves in the pulp can respond to various stimuli (heat, cold, pressure, osmotic fluid movement, chemical irritation...), but regardless of the stimulus, the sensation registered is pain!!

Now let's look at endodontic disease, how it occurs and its significance to the patient.

Crown Fracture With Pulp Exposure

When the crown of a tooth suffers a significant fracture, there is often obvious *pulp exposure*. What I mean by obvious is that the hole is large enough to be seen with the naked eye and you would be able to place the tip of a dental explorer into the pulp chamber through the

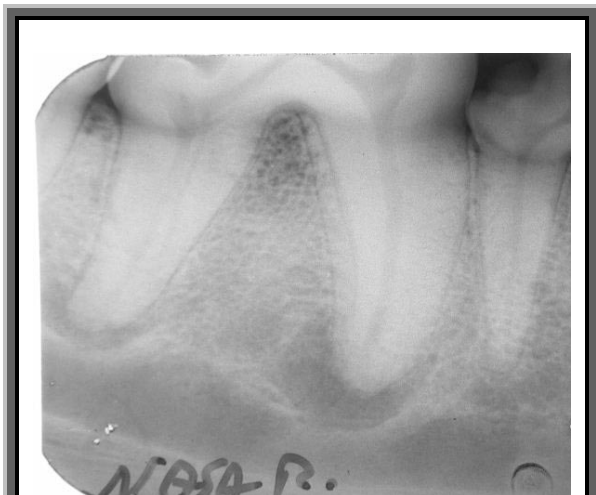

Figure #15.3. This radiograph of a fractured right mandibular first molar tooth clearly shows the dramatic decrease in bone density (due to chronic osteomyelitis) at the apices of both roots. The tooth was not loose, there was no fistula or gingival inflammation associated with this lesion. The problem is buried deep within the mandible where it can only be assessed radiographically.

exposure. When this has occurred, there has been significant trauma to the pulp in that an entire section of this organ has been torn away from the tooth. The remaining pulp is now exposed to the outside world and is, therefore, exposed to mechanical, chemical and, most significantly, bacterial insult. As with any open wound, pulp exposure causes pain.

Exposed pulp will *always* become inflamed, just as any damaged tissue will – it has no other choice. What happens next and in what time frame is variable, but the end result is always the same. The pulpitis will become irreversible as the pulp succumbs to bacterial infection and the pulp will die.

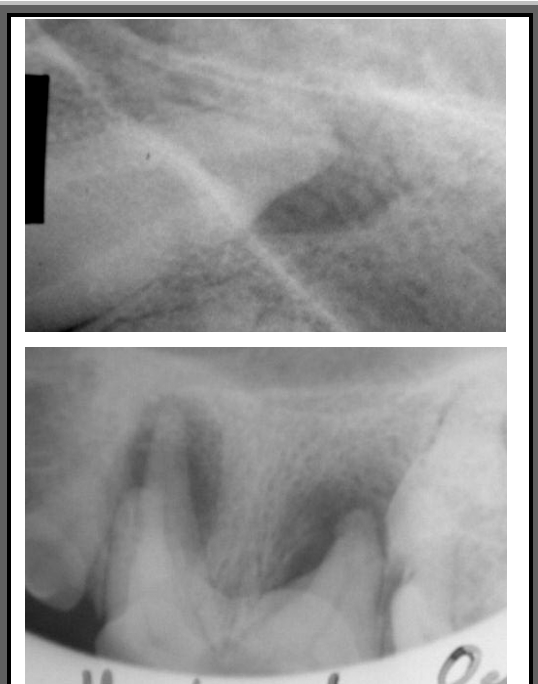

Figure #15.4. Radiographs of the periapical areas of a fractured left maxillary canine tooth and left maxillary fourth premolar tooth. In both cases, the chronically open pulp chambers have allowed extensive periapical infection and bone loss. Frequently the radiographic signs are more subtle, but with a little practice are easy to identify. In neither case was there any gingival inflammation, fistula development, tooth mobility or facial swelling. Again, the assessment of the situation relies on diagnostic intra-oral radiographs. On the other hand, if there is a crown fracture with pulp exposure, development of periapical pathology is an inevitable outcome without endodontic treatment.

As the pulp is dying, there is the intense stabbing pain that some of us know personally as “tooth ache”. Once the pulp is dead (days/weeks/months), the pain subsides (dead tissue sends no signals). Now the pulp chamber is filled with necrotic soft tissue and bacteria – a really good culture medium. The bacteria and their toxins will eventually ooze out through the apical delta and into the periapical periodontal space, leading to a chronic, periapical periodontitis, which is painful, but in a more diffuse manner than the pulpitis. As long as the tooth is not being used, it is tolerable, but biting or chewing with this tooth will push it into its socket, placing more pressure on the inflamed periapical tissues. Therefore, the animal is likely to favour this tooth by chewing on the other side of its mouth.

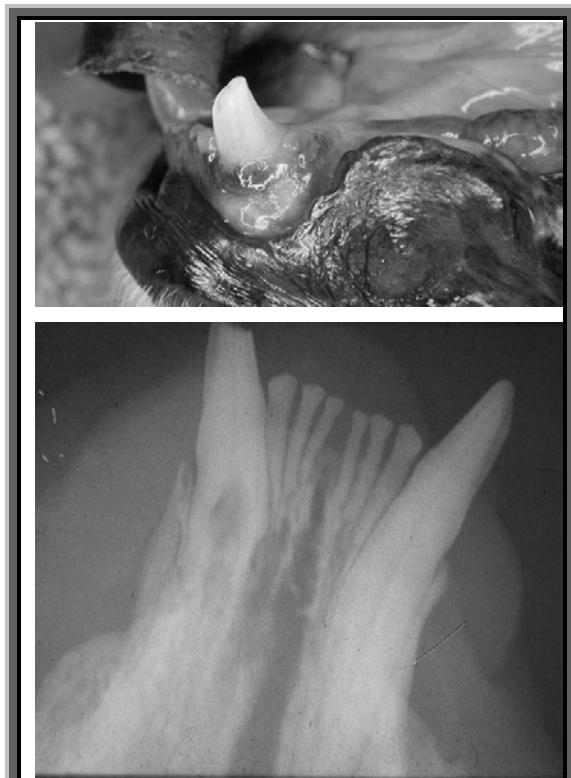

Figure #15.5. This fractured left mandibular canine tooth had been associated with recurrent mandibular swellings that responded to antibiotics. The radiograph shows the dramatic loss of root tissue as well as damage to the surrounding bone. Extraction of the tooth resulted in pathologic fracture of the mandible. All of this, and years of pain could have been prevented by endodontic treatment when the tooth was first broken rather than monkeying around with antibiotics for a few years.

Fractured teeth often have more calculus than the other teeth in the mouth. The porous dentin is more plaque retentive than smooth enamel. A fractured tooth is sensitive so the animal uses it less, chewing on the other side of the mouth instead.

If you notice that the upper left fourth premolar has lots of calculus but the rest of the mouth looks clean, chances are, that dirty tooth has a fracture. Look closely at the shape of the crown. Is it different from the upper right fourth premolar? Usually the tip of the mesial cusp is missing, making the crown look shorter than the healthy tooth.

In time, a periapical periodontitis may do many different things. It may develop into a periapical abscess, which is intensely painful until it finds somewhere to fistulate and release pressure. It may develop into a periapical granuloma, which causes a dull chronic pain. It may develop into a periapical cyst, which will be destructive of surrounding structures as it expands. As well, the inflammation may cause external root resorption.

Regardless of the specific course the lesion takes, all cause pain to some degree and all are associated with a chronic infection that the body cannot possibly resolve. The source of the infection is the bacteria inside the tooth and there is no longer any way for the body to reach in there to clean up the mess. Antibiotics may offer short-term symptomatic relief, **but they have no effect on the source of the infection.**

Most of these lesions will never offer obvious external signs such as facial swellings or large draining fistulae. However, if you think you are seeing broken teeth that are not causing problems, I would say all you have to do is start taking some intra-oral dental radiographs. Then you will see the pathology.

Crown Fracture with Near-Exposure

Many teeth suffer crown fractures without an obvious pulp exposure. But, if you consider the porous nature of dentin and the odontoblastic processed within the tubules, you will see that

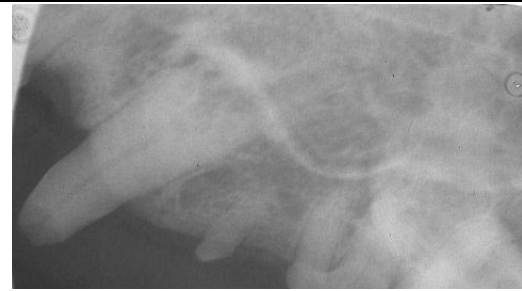

Figure #15.6. This left maxillary canine tooth in a cat has had a chronic pulp exposure, which has resulted in inflammatory external root resorption. The apical half of the root has been destroyed and so conventional root canal therapy was not an option. Again, there was no fistula, facial swelling or gingivitis associated with this lesion. Assessment is by dental radiography.

there really is pulp exposure at the microscopic and cellular levels (Figure #s 7.4 & 7.5, pages 27 & 28). For one thing, odontoblastic processes will have been severed and so there is cellular damage from the fracture. Also, the open dentin tubules are large enough to act as conduits through which bacteria can gain access to the pulp chamber.

Exposed dentin is sensitive to many stimuli, including heat, cold, touch and osmotic gradients. The current theory to explain dentin sensitivity is known as the *hydrodynamic theory*. It suggests that the pain associated with dentin

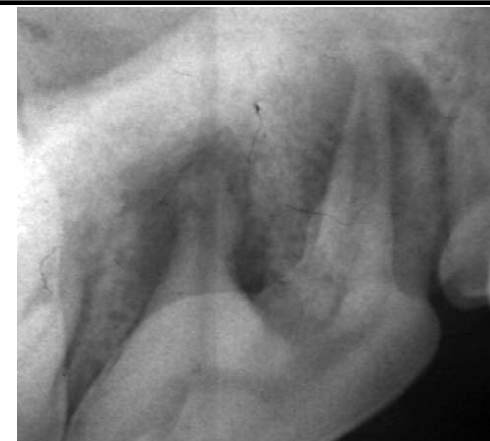

Figure #15.7. The crown of this right maxillary fourth premolar had a slab fracture with a near-exposure. The pulp has obviously become infected and necrotic, as there is dramatic periapical bone loss due to chronic osteomyelitis. There is also some external root resorption along the distal root as evidenced by the irregular contour of this root.

exposure is due to fluid movement pulling on the odontoblastic processes and the nerve fibers within the tubules. If air passes over exposed dentin, it desiccates the surface, decreasing the surface tension and causing fluid to flow from the pulp toward the surface. Sweet drinks create an osmotic gradient that will also irritate exposed dentin by drawing fluid through the tubules. Anything physically touching the exposed surface decreases surface tension and draws fluid through the tubules. All of these cause pain.

The pain associated with dentin exposure will stimulate inflammation. Inflammation causes vasodilation and edema but since the pulp is constrained in the rigid confines of the pulp chamber, the increased pressure within the pulp may strangulate the venous return and the pulp may die (avascular necrosis). Once the pulp is dead, there is no vital soft tissue occluding the dentin tubules, which become open conduits for bacteria. Now the pulp is not only necrotic, it is also contaminated.

Another scenario sees the odontoblasts below the fracture becoming necrotic because of the

traumatic tearing of their processes, thus leaving the dentin tubules open to allow the passage of oral bacteria into the pulp chamber to cause infection and septic necrosis of the pulp.

The bacteria do not really wait for the pulp to die before they start to colonize the tubules. The demise of the pulp is likely due to a number of noxious stimuli working simultaneously, including the initial cellular trauma, hydrodynamic irritation and bacterial contamination.

Teeth with near-exposure do present a diagnostic challenge. I have seen a number of fourth upper premolars and first lower molars with very similar looking fractures. Some of them have obvious endodontic disease evident on radiograph and others have no clinical or radiographic signs of endodontic disease. So, unlike teeth with obvious pulp exposures (which have a certain outcome of pulp necrosis), teeth with dentin exposures may or may not survive the injury. In one dog, the right and left mandibular first molars had coronal damage that looked virtually identical on visual examination. On the left, there was obvious pulp necrosis and periapical disease and on the right everything looked fine both at initial evaluation and on follow-up a year later.

One might ask, "How near is too near for the

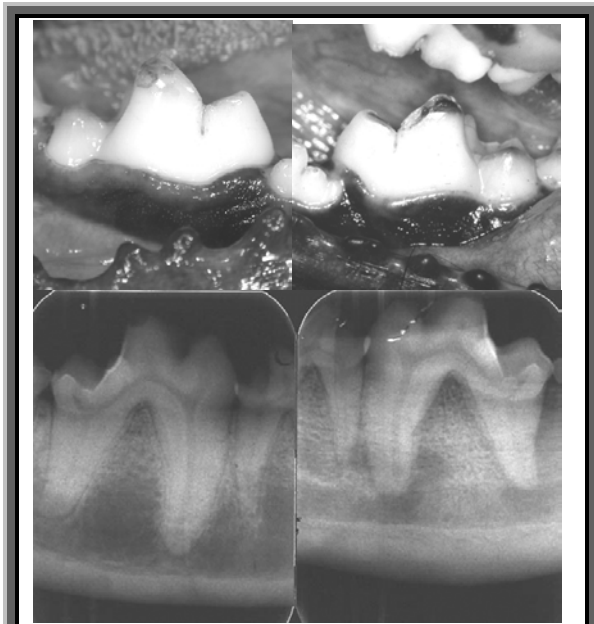

Figure #15.8. The coronal damage to the right and left mandibular first molars in this dog were virtually identical on visual examination. The radiographs indicate that the left molar (seen on the right) has obvious endodontic disease whereas the right molar (seen on the left) has remained radiographically normal on follow-up examination one year after these films were exposed.

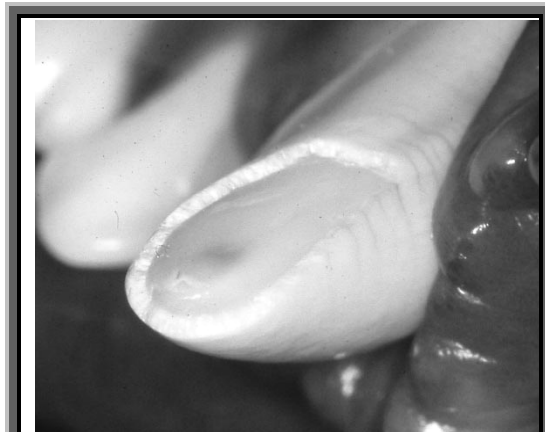

Figure #15.9. The dark spot in the centre of the fracture site was pink, indicating a very near pulp exposure overlying vital pulp. Rapid action by the owner in seeking treatment for this tooth allowed for a successful outcome for a partial vital pulpotomy. Delay of even a week in cases such as this could result in pulp necrosis and the need for extraction or full root canal treatment.

pulp to survive?” There is no one answer. Many factors are involved, including the age of the tooth at the time of injury, the thickness of the dentin remaining between the outside world and the pulp and host response to the injury. If the injury is recent and you are able to see a pink spot in the fracture site, you are seeing what is referred to as a *pulpal blush*. This means that the dentin remaining between you and the pulp is so thin that the pulp’s pink colour is showing through. These are *very-near-exposures* and will definitely need endodontic treatment or extraction.

An old very-near-exposure will not have a pulpal blush as necrotic pulp is not pink. You may see a dark spot, which is the necrotic pulp showing through the thin layer of dentin. More often, however, the exposed dentin surface will be covered by calculus. The porous dentin is far more plaque-retentive than smooth enamel and usually the animal will avoid chewing with these teeth. Therefore, plaque and calculus accumulate rapidly on these teeth, obscuring your view of the fracture. At first look, you may not even notice that the tooth has a fracture. That is why you have to look carefully.

Minor Chip Fractures

Teeth frequently suffer minor chip fractures in which the dentin is exposed, but there is still a thick layer between the pulp and the outside world. The tooth is not completely without reparative capacity and will not roll over and die at the slightest insult. So these minor chip fractures usually do not require treatment.

Acute chip fractures do expose the dentin and lead to sensitivity, so the patient can be made more comfortable and the chances of the tooth surviving boosted by coating the fracture site with a dentin bonding agent.

What factors determine if a fracture is a minor chip or a near exposure? A major factor is how close the fracture comes to the pulp. Recall that the dentin wall of a tooth is thin when the animal is young and it gets thicker as the tooth ages. Therefore, a fairly minor-looking fracture on a young tooth may come dangerously close to the pulp while the same fracture on a ten-year-old tooth would be insignificant.

When presented with a tooth that has a crown fracture without pulp exposure, you should rule out endodontic disease. This would be so much easier if our patients could talk, but they cannot.

Question the owner about any changes in behaviour, eating or chewing habits. Radiograph the damaged tooth and also radiograph the contra-lateral counterpart for comparison. If the pulp chamber of the chipped tooth is larger than the same tooth on the other side of the head, the chipped tooth has been dead for a long time. Also look carefully at the periapical periodontal space for evidence of widening of the space and/or bone loss.

Worn Teeth

Some dogs love to chew abrasive things such as rocks, tennis balls or their own fur (flea allergy dermatitis dogs). Some dogs have abnormal tooth-to-tooth contact due to malocclusion and this can cause wear. Whatever the cause, the wear may be significant enough to lead to near exposure or pulp exposure. This is just like a crown fracture with pulp exposure.

In some instances, the wear on the crowns is gradual and the teeth have time to react. As the wear breaks through the enamel and exposes the dentin, the odontoblasts beneath the worn area are stimulated (via the hydrodynamic theory). This causes these odontoblasts to produce tertiary dentin. So the pulp retreats from the noxious stimulus and leaves tertiary dentin in its wake (Figure #7.6, page 28).

Tertiary dentin is darker than normal dentin. When you look at a worn tooth, you are likely to see the outer ring of enamel, then the off-white primary and secondary dentin and in the centre, a dark spot of tertiary dentin. But how do you tell tertiary dentin from necrotic debris plugging an open pulp chamber? Tertiary dentin is typically reddish-brown, hard and smooth and is shiny even when dry. Debris plugging an open chamber is typically black, it yields when probed with a dental explorer and it is dull looking when dried.

As long as the rate of wear is gradual, the tooth can get worn right down to the gum-line without ever causing pulp exposure or irreversible pulpitis. However, if the rate of wear is just a bit faster than the rate of tertiary dentin production, eventually, the wear will get too close to the pulp leading to irreversible pulpitis and pulp necrosis. Once the pulp is dead, further wear will break through the previously produced tertiary dentin, resulting in pulp exposure.

So, worn teeth may be all right or they may have endodontic disease. How do you tell the difference? Radiographs, of course.

Discoloured Teeth

It is quite possible (common in fact) for teeth to suffer pulp necrosis without any crown fracture. A tooth that is misaligned and subject to abnormal occlusal trauma will often develop a traumatic pulpitis, which can lead to pulp necrosis. A poorly contoured restoration that leads to abnormal occlusal contacts can have the

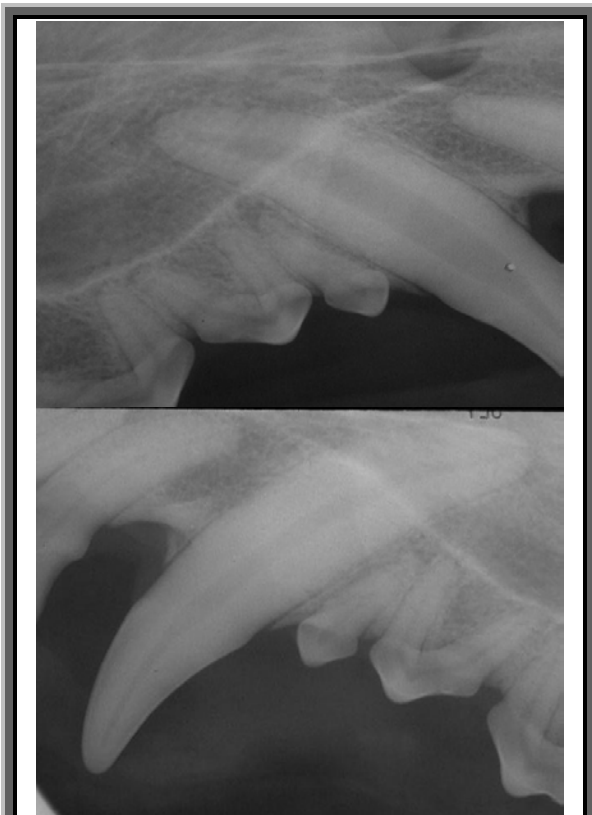

Figure #15.10. These radiographs are of the same dog. The upper film is of a discoloured right maxillary canine tooth and the lower one is of the clinically normal left maxillary canine tooth. You can see that the pulp chamber in the right canine is much larger than in the left, indicating that the pulp in the right tooth died a long time ago, halting dentin production while the vital pulp in the left canine continued to produce dentin, making the pulp chamber smaller. These dramatic differences in pulp chamber size take a year or more to develop and so would not be seen in acute pulp necrosis. Though subtle, there was a definite periapical radiolucency indicating periapical inflammation.

same result. Ask anyone who has ever had an oversized filling how much discomfort it caused.

Blood-borne infection may colonize the pulp leading to pulpitis and pulp necrosis. This is likely a rare event.

Trauma to the head may disrupt the blood supply to the tooth leading to an avascular necrosis. Bear in mind that the pulp has no collateral circulation. The only way into or out of the tooth is through the apical delta.

Blunt trauma to the tooth may lead to a traumatic pulpitis, leading to pulp necrosis.

Whatever the cause, a traumatized pulp will develop a pulpitis. If the insult is mild, the pulpitis may be reversible and the tooth may survive. If the insult is more serious, the inflammation may become irreversible, resulting in pulp necrosis. As the pulp dies, the endothelium of the blood vessels falls apart releasing red blood cells. RBCs are larger than dentin tubules, but once the RBCs breakdown, the hemoglobin will seep into the dentin tubules and cause intrinsic staining of the dentin. The result is a crown that looks pink/purple. As the hemoglobin degrades, the crown will change to a gray or light brown colour.

Generally, purple/gray/tan teeth have no infection. However, as the pulp tissue degrades, intercellular contents are spilled and these include a host of mediators of inflammation. They will seep out through the apical delta, leading to periapical periodontitis.

A retrospective study of my records (published in the *Journal of Veterinary Dentistry*, Vol 18, #1) found that discolouration of the crown is a very reliable predictor of pulp necrosis. Gross signs of pulp necrosis were found in 92.2% of discoloured teeth. Since histology was not done, it is uncertain if the pulp in the remaining 7.8% of teeth with grossly vital pulp was healthy or not. These vital teeth may have had pulpitis that had not progressed to necrosis by the time of presentation. Further data on 21 discoloured teeth found that 100% had pulp necrosis at treatment.

This is one area where dental radiographs, though valuable and essential in assessing the situation, often gave less than dramatic results. In the published data, there were radiographic signs of endodontic disease in fewer than 50% of the teeth with confirmed pulp necrosis. This is likely due that fact that pathological changes

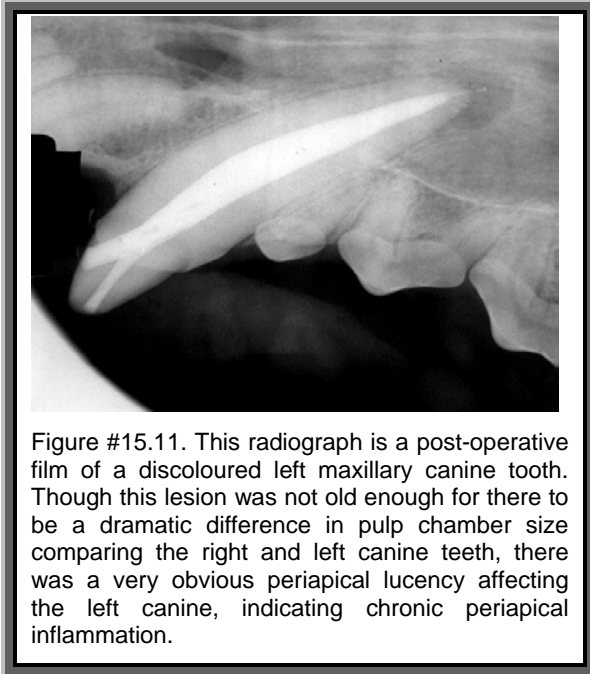


Figure #15.11. This radiograph is a post-operative film of a discoloured left maxillary canine tooth. Though this lesion was not old enough for there to be a dramatic difference in pulp chamber size comparing the right and left canine teeth, there was a very obvious periapical lucency affecting the left canine, indicating chronic periapical inflammation.

would take considerable time to become radiographically evident and the patients were presented for treatment shortly after the pulp necrosis.

Based on the findings, it seems safe to conclude that discoloured teeth have or soon will have necrotic pulp. The body does not want necrotic tissue, but the inflammatory process cannot reach inside the tooth to remove it. Therefore, we must remove it by either doing root canal treatment or by extracting the tooth.

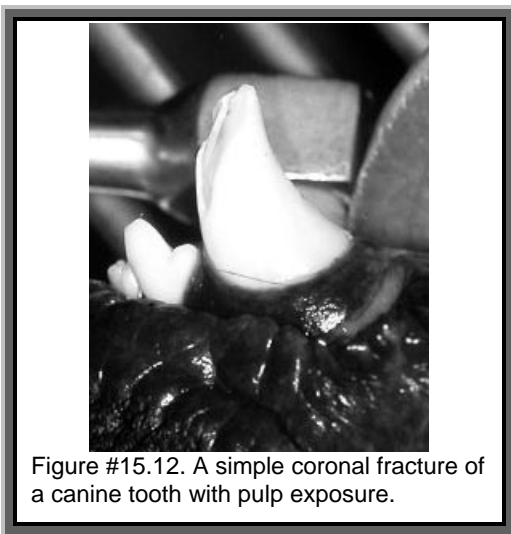


Figure #15.12. A simple coronal fracture of a canine tooth with pulp exposure.

Treatment Planning

This is the easy part. Teeth with endodontic disease or pulp exposure require treatment and there are only two options; endodontic therapy (of some sort) or extraction. The endodontic therapy might be indirect pulp capping, direct pulp capping or total pulpectomy.

Presentation	Treatment Options
Crown Fracture or Wear with pulp-exposure.	Endodontic treatment or extraction.
Crown Fracture or Wear with near-exposure.	Endodontic treatment or extraction.
Chip Fracture or Wear with tertiary dentin.	Radiographic evaluation and possibly endodontic treatment or extraction.
Pink, purple, gray or tan discolouration of the crown.	Endodontic treatment or extraction.

Vital Pulpotomy vs. Total Pulpectomy

For now, let us consider the simplest of cases in which a dog has taken the tip off a canine tooth. The pulp is exposed, but there is no damage near or below the gum line and the remaining two thirds of the crown is intact (Figure #15.12).

In cases where the pulp is exposed, there are two main treatment options to consider. The first is extraction. This would achieve the objectives of removing a source of considerable pain as well as a conduit of infection. The other option is endodontic treatment of some type.

Endodontic treatment options include *total pulpectomy* or *partial vital pulpotomy*. Each option has its advantages and disadvantages, indications and contra-indications. A thorough understanding of dental and endodontic anatomy, development and physiology is required to understand what follows, so review those sections before proceeding.

In *vital pulpotomy*, also known as *partial vital pulpectomy*, only the coronal portion of the pulp is removed. Typically, a sterile bur, in a high-speed hand piece is used to amputate the pulp to a depth of about 6-8 millimeters. The rest of the pulp is left inside the tooth. Next, various dental materials are placed inside the chamber on top of the pulp stump to protect the pulp and to seal the

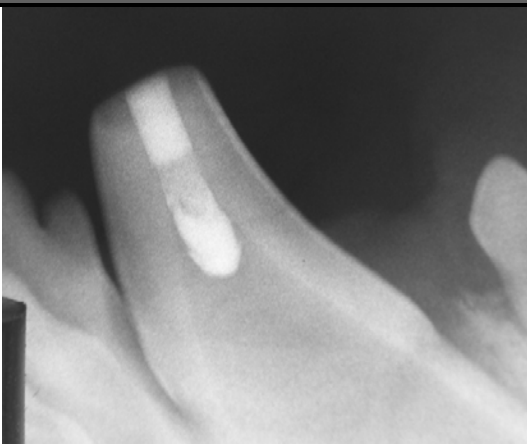


Figure #15.13. A post-operative radiograph of the crown of the mandibular left canine tooth following partial vital pulpectomy and direct pulp capping. Inside the tooth there are layers of mineral trioxide aggregate in contact with the pulp, then a layer of glass ionomer and finally a layer of bonded composite resin.

tooth against the ingress of bacteria that would kill the pulp. Traditionally, the material placed in direct contact with the freshly cut pulp stump has been a calcium hydroxide preparation. The very high pH actually causes a surface necrosis of the pulp it touches. Undifferentiated free cells in the pulp below the zone of necrosis are stimulated to become odontoblasts and start producing dentin (this dentin produced in response to some irritation is known as tertiary or reparative

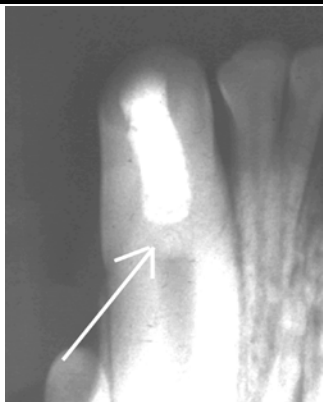

Figure #15.14. This radiograph shows the dentin bridge that has formed between the vital pulp and the restorative materials placed inside the pulp chamber of the crown of this canine tooth. As the animal ages, the chamber in the root should get smaller due to secondary dentin production.

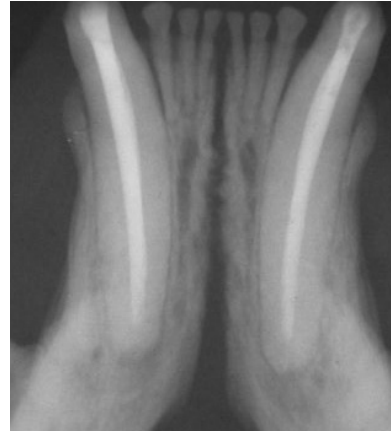


Figure #15.15. An intra-operative radiograph of a cat mandible showing the canine teeth following debridement and obturation of the canals but prior to final restoration of the access holes in the crowns. The original films showed obvious radiolucencies affecting both canines.

dentin). The bulk of the pulp inside the tooth remains unaffected by the treatment and so normal secondary dentin production continues as before within the rest of the tooth.

More recently, mineral trioxide aggregate has been found to have many advantages over calcium hydroxide and is being used in its stead.

On top of the pulp capping material, there is frequently an intermediate restorative such as a glass ionomer and then the final restoration of the access hole is made with a bonded composite resin.

In *total pulpectomy*, the entire pulp is removed from the tooth and the chamber (root canal) is filled with dental materials. Once this is done, the odontoblasts are all gone – there can be no more dentin production of any kind in the treated tooth. Its wall will never get any thicker no matter how long the animal lives. The radiograph of a cat mandible shows the mandibular canines after the canals have been debrided and obturated (filled), but prior to final restoration of the access holes in the crowns.

A young animal with a recent dental fracture needs IMMEDIATE attention if the tooth is to be saved!!!

The advantages to partial vital pulpectomy and direct pulp capping include:

- usually faster and cheaper than total pulpectomy,
- keeps the pulp intact so the tooth can continue to mature,
- maintains a source of moisture to the dentin, helping to keep it elastic (flexible).

The big disadvantage is, it may not work! If a partial vital pulpotomy and direct pulp capping is done and it fails, that means that the pulp dies anyway. During the time the pulp is dying, there will be acute toothache. Once the pulp is dead, you have the same problems as you get with an untreated broken tooth – chronic pain and infection. In fact, with the crown sealed with a bonded restoration, any pressure that builds up inside the tooth (due to gas production by bacteria) must be released through the apical delta.

To monitor for signs of success or failure, it is very important that the tooth be re-radiographed (intra-oral dental radiographs under general anesthesia) at least once (six to twelve months post-operatively) and preferably every few years thereafter. We need to see if the pulp chamber is getting smaller and if a dentin bridge has formed between the pulp capping material and the pulp. We also want to assess the periapical region for signs of inflammation. The only way to do this is with good quality dental radiographs.

In humans, pulp-capping procedures have been known to fail as much as twenty years post-operatively. Therefore, once a tooth has had a partial vital pulpotomy and direct pulp-capping, it requires long-term follow-up and its prognosis always remains open.

The main advantages of total pulpectomy are the obverse of the disadvantages of pulpotomy. Once a full root canal is done, there is no pulp left in the tooth to cause any trouble. Therefore, you do not have to worry about how the pulp is doing. Follow-up radiographs are still recommended to assess the health of the periapical tissues, but the chances of things going badly down the road are greatly reduced.

The disadvantages of total pulpectomy include:

- cessation of dentin production so tooth wall never gets thicker,

- theoretical gradual dehydration of dentin causing tooth to become more brittle over the years (not proven beyond doubt),
- usually takes longer than pulpotomy and so costs more in the short term,
- often requires the drilling of an access hole to allow straight-line access to the apex of the tooth and this creates a weak spot on the crown.

So how do I decide which treatment to choose when I am presented with a fractured tooth?

I consider several factors in treatment planning for a fractured tooth. I need to know how old the animal is (vis-à-vis root wall thickness), how long ago the tooth was damaged (vis-à-vis how long the pulp has been exposed to oral bacteria and mechanical trauma from chewing) and how committed the owners are to follow-up (vis-à-vis getting the necessary radiographs to monitor the tooth in the future).

In a young dog or cat (less than 18 months of age usually) with a recent fracture (less than 48 hours), I like to do partial vital pulpotomy and direct pulp capping to keep the tooth alive, allowing it to grow in strength and maintain its elasticity. For this to be possible, it requires **immediate action!** So if you see a patient that fits this profile, **drop everything and treat or refer immediately!** I will do everything I can to see the patient without delay as the chances of success really depend on fast action.

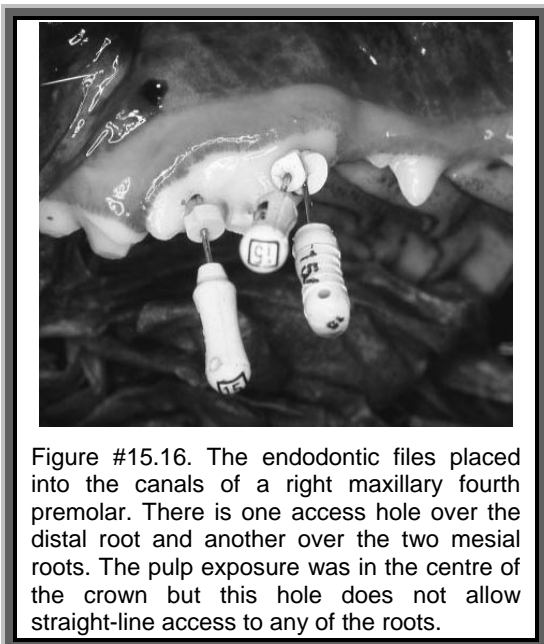
In a mature animal, I usually go straight to total pulpectomy. Once the animal is two years old or more, the tooth has the majority of its strength, so keeping it alive is of less value than in a younger patient. Also, the smaller pulp of a mature patient is far less resilient, it has fewer undifferentiated cells to become odontoblasts to produce the dentin bridge and it is less likely to survive the initial trauma and the treatment itself. So the prognosis for a partial vital pulpotomy in a mature animal is not good.

There are, of course, exceptions to these generalities. There are also animals that fall into gray zones (between 18 and 24 months of age or fractures 3 to 5 days old). These need to be evaluated carefully, in consultation with the owners, to decide what is most appropriate in their specific situation. Sometimes I do the pulpotomy and sometimes I do the full root canal and sometimes I extract the tooth.

I should also mention that there is a procedure to rescue immature teeth that have already suffered pulp necrosis. For example, if dog fractures as canine tooth while it is erupting and the apex is still wide open and the condition goes untreated, allowing the pulp to become necrotic, it is not possible to do a partial pulpotomy. Nor does the thin root wall and open apex allow for standard root canal therapy.

In these cases, a procedure known as *apexification* can be done. Here, the necrotic pulp is gently removed from the canal. The canal is gently lavaged with saline and then it is packed with a calcium hydroxide paste and the hole in the crown restored. The calcium hydroxide paste should stimulate the tissues around the root tip to produce osteoid or BLCL (bone-like, cementum-like) tissue, thus forming a closed apex.

The tooth is re-radiographed and the calcium hydroxide paste dressing changed every 3 to 6 months until a solid apex has formed, at which time the canal is again debrided and then filled in the manner typical of regular root canal treatment. This preserves the tooth, but it will always be thin walled in both crown and root and so my own opinion is that it is a heroic effort with a dubious long-term prognosis. It takes several anesthetics and surgeries and so ends up being quite expensive. It is far better to treat these immature teeth right away and keep the pulp alive.



Total Pulpectomy

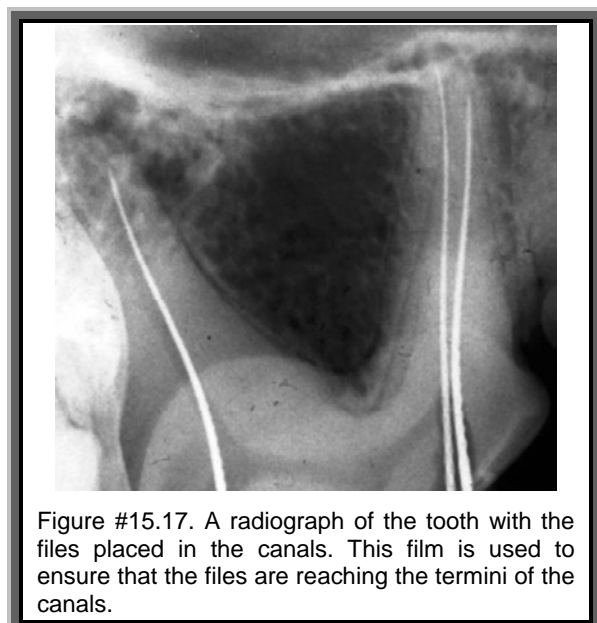
Total pulpectomy has been alluded to in previous sections, but a bit more detail on this procedure is in order.

Indications include crown fractures or abrasive wear with pulp exposure or near pulp exposure in mature teeth or of durations greater than a few days and coronal discoloration. The purpose is to remove all pulp and/or bacteria from the endodontic chambers and then densely fill the chambers with antibacterial and dimensionally stable materials.

The first step is to create access holes in the crown that will allow the straight-line access to the apical portion of the canals, as the instruments do not like to work around bends and curves. For the canine teeth, the access hole is typically placed on the mesial face a few millimeters coronal to the free-gingival margin. For the fourth upper premolar, the distal root is assessed through one hole and the two mesial roots through another.

Endodontic files and irrigating solutions are used to remove any pulp or necrotic tissue and bacteria and to shape the canals to accept the filling materials.

With the canals thoroughly debrided and shaped, the canals are filled, typically with a sealer cement and gutta percha points and then the access holes are filled with bonded composite restorations.



Follow-up radiographs are recommended for 6 to 12 months post-operatively and then again whenever the opportunity arises.

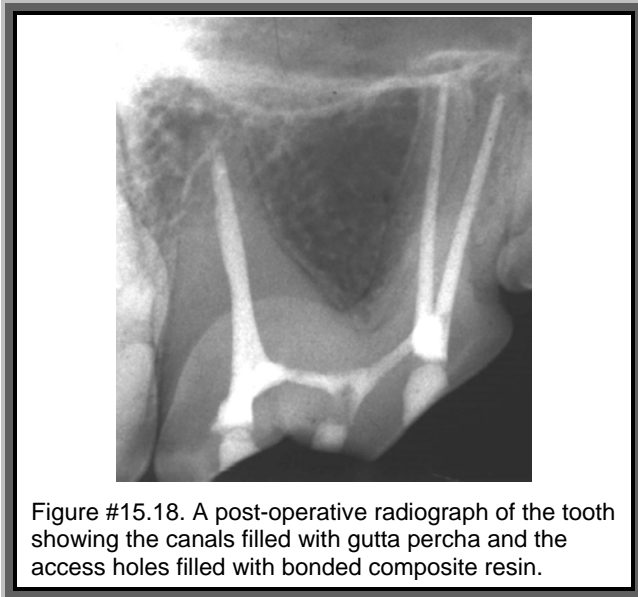


Figure #15.18. A post-operative radiograph of the tooth showing the canals filled with gutta percha and the access holes filled with bonded composite resin.