

## PROBING DEPTH

One of the most important clinical parameters to be measured and recorded when doing periodontal evaluation is *probing depth*. However, taking a measurement and being able to accurately interpret the meaning of the raw data are two different things. In order to recognize abnormal probing depths, we must know what the normal probing depth is supposed to be.

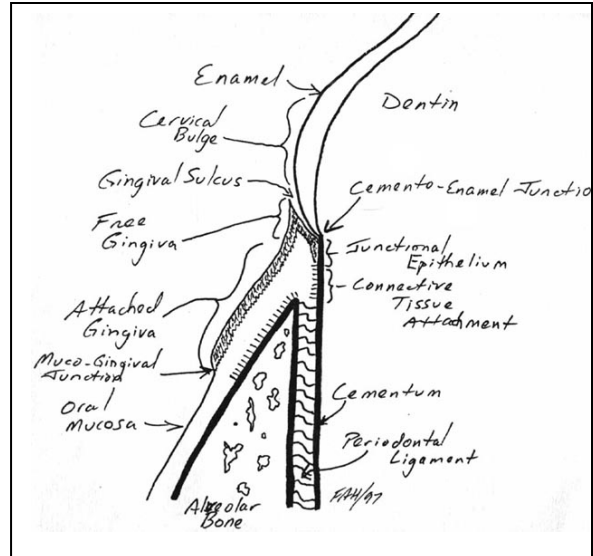
It is very common to see in literature and online that for dogs, normal probing depth is 1-3 millimeters. This is an unfortunate and horrible over-simplification which can lead to misdiagnosis. It would be like saying the optimum body weight for the domestic dog (regardless of breed) is 20 to 40 kg.

A brief review of normal periodontal anatomy may be in order so have a look at this - <http://www.toothvet.ca/PDFfiles/PerioAnat&Phy sio.pdf>.

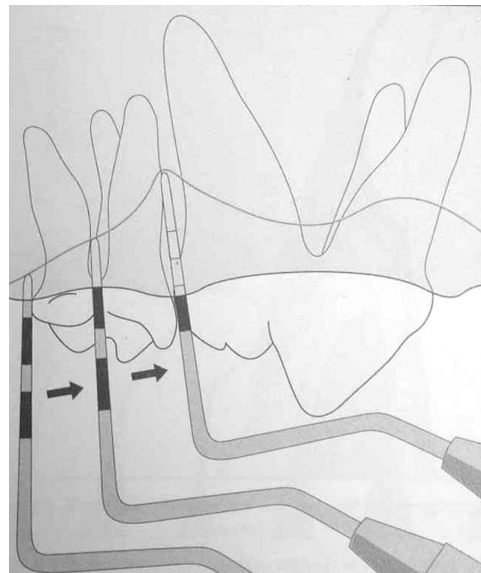
Measurement of probing depth is done to determine where the soft tissue (gingiva or periodontal ligament) attaches to the hard tissue (enamel, cementum or bone). In many previous papers I have stated that gingiva and periodontal ligament will only attach to cementum and alveolar bone. From a practical standpoint, this is basically true. However, it is more accurate to say that healthy gingiva can attach to clean enamel with hemidesmosomes. In germ-free animals or in patients with exceptional gingival health, probing depth may be zero (no gingival sulcus at all). In reality, our patients almost never have gingival attachment to enamel and so the highest level of gingival attachment we should expect would be at the cemento-enamel junction.

How to Probe:

To measure probing depth, one takes a periodontal probe, inserts it gently below the gingival margin until it meets resistance and the depth of insertion is read from the graduations on the end of the probe. In the diagram to the right, the probe is graduated in alternating light and dark bands, each 3 millimeters wide. At the far left of the image, the probing depth (distal to

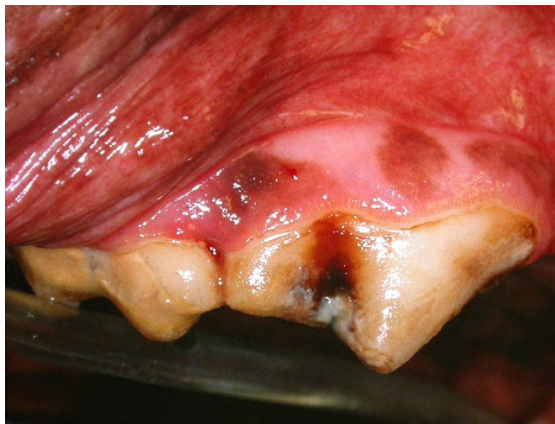

the maxillary first molar) is 1.5 millimeters. Moving to the right, the next measurement (at the furcation of the first molar) is 3 millimeters and then in the space between the first molar and fourth premolar, the probing depth is 10 millimeters. This inter-dental space (between upper fourth premolar and first molar) is one of many places that is at high risk for the development of periodontal disease and so you should expect trouble her and go looking for it, even if the tissues look normally on visual examination.

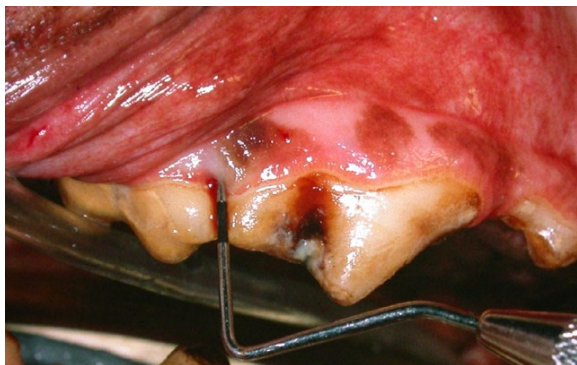

From Emily P, Penman S. Handbook of Small Animal Dentistry, Pergamon Press, 1990.

The clinical images on this page offer an example of this in clinical case. On visual examination of the right maxillary fourth premolar and molar, we see some thin mineral accumulations on the crowns and mild marginal gingivitis but no obvious indication of advanced periodontal disease is seen. This is yet another example of how periodontal disease is a hidden disease and cannot be accurately assessed in a conscious patient. For more on that issue, have a look at [http://www.toothvet.ca/PDFfiles/perio\\_hidden.pdf](http://www.toothvet.ca/PDFfiles/perio_hidden.pdf).




The next photo shows the periodontal probe inserted into the hidden periodontal defect in the inter-dental space to a depth of 8 millimeters. More investigation is required because we still do not know if the associated bone loss is affecting the support of the distal root of the fourth premolar, the mesial root of the first molar or both. As well as intra-oral dental radiographs, this area is going to require periodontal surgery to elevate a mucogingival flap in order to access and properly assess and treat this deep periodontal pocket.



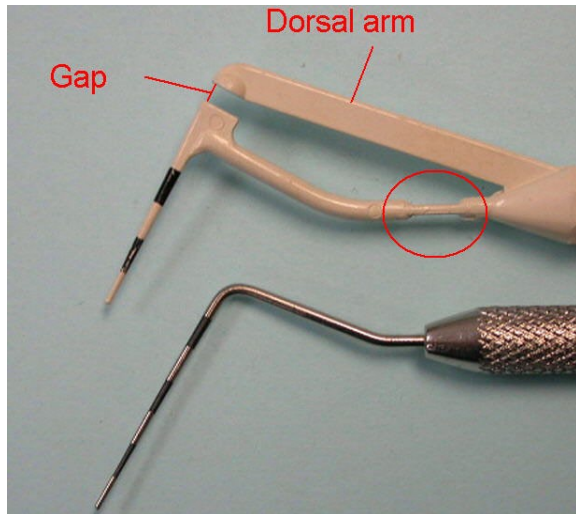
There are many styles of periodontal probes available, including some high-tech electronic ones. Most of my readers will be using manual probes. Each has a straight 'business-end' with a blunted tip and some form of graduation along its length.

In the photo below, the probe second from the left is broad but flattened. The one second from right has a round ball on the end to make it very blunt. I favour probes that have alternating black and neutral bands, each 3 millimeters wide such as shown to the far right.



Now that you have a probe and know where to place it, you need to know *how* to place it. Probing must be done delicately to obtain an accurate reading and to avoid causing damage to the gingival attachment apparatus.

Every tooth should be probed around its entire circumference and all abnormal probing depths records on the permanent dental chart for that day's treatment.

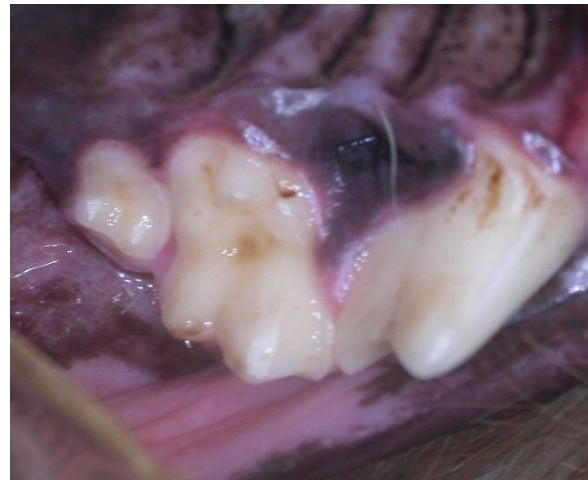

The plastic probe to the top of the photo above is known as a Sensor Probe. It comes from Pro-Dentec and is distributed by Zila Therapeutics (<https://www.denmat.com/Oral%20Hygiene/Preventative/Probes/Pack/>). The concept is that as the probe is introduced into a sulcus/pocket, it will eventually meet some resistance at which point, the arm that the probe is on will bend at the small 'hinge' (circled). As resistance increases the gap between the probe arm and the dorsal arm closes. That tells the operator that they have applied an appropriate amount of probing pressure.

It takes only a very light pressure to close the gap and practicing with sensor probe is a great way to develop the delicate touch required to probe accurately and atraumatically. I would recommend that every clinic get some of these and that all staff who do probing be encouraged (required) to practice with a sensor probe on a regular basis.

Probing with too much force can cause the tip of the probe to penetrate the junctional epithelium. This will result in damage to the very tissues we are trying to preserve, will over estimate the probing depth and over estimate the bleeding index. Probing with too little force will under estimate the probing depth. So it is important to develop the right touch.

There are areas in the mouth that can be hard to probe. For example, in a small dog, the space between the maxillary first and second molar is sometimes very tight - so tight that there is no room to get any instrument between the teeth.



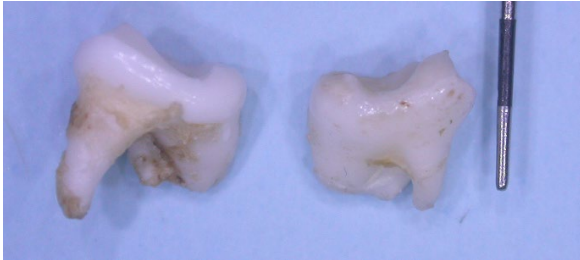
The photo above of the left maxillary fourth premolar and molars of a four-year-old Yorkie shows that very tight proximal contact. The tight contact between the molars makes it a difficult area to assess but it also makes it an area highly predisposed to the development of periodontal disease, so it must be assessed accurately. A good headlight and magnification can really help as well as careful yet diligent probing. If you see a purulent discharge in this interdental space, as in this photo, chances are there is periodontal disease and the second molar will need to be extracted. Then the first molar needs careful assessment to see if it can be saved.

So what is normal probing depth?

Now we finally get to discussing what is normal with respect to probing depths. In the normal, healthy situation, we want the free gingival margin to be coronal to the cemento enamel junction and the junctional epithelium to be attached to the cementum right at the cemento enamel junction. In other words, the normal probing depth is the depth of the normal gingival sulcus for that location on that tooth in that patient (still not committing to any numbers).

In a large Labrador, the width of the gingival band, from free gingival margin to mucogingival junction, might be 15 millimeters. For a large tooth in a large dog with a wide band of gingiva, I would not be worried about a probing depth of up to 4 millimeters if everything else was normal (no gingival recession for instance).

At the other end of the scale, the maxillary second molar of a 1.2 kg Chihuahua might have a total root length of 2 millimeters. Therefore, probing depth of 2 millimeters would constitute end-stage periodontal disease and the absolute need for extraction of that tooth.



Normal probing depth is affected by the size of the tooth, particularly the length of the root, and the width of the gingival band wrapping around the tooth. So for some patients/teeth, a probing depth of 3 millimeters would be perfectly fine and for others, it would indicate end-stage periodontal disease.

One way to look at normal probing depth is that it is the depth from the free gingival margin to the cemento-enamel junction. On a very small tooth, this might be 0.5 millimeters. On a very large tooth, it might be 4 millimeters. We record probing depth in millimeters but interpret that number in relationship to the size of the patient and tooth

As important as probing depth is to measure and record, the raw data is meaningless unless interpreted in relationship to the specifics of the anatomy of the teeth. As well as probing depth, we need to also record gingival recession or hyperplasia and we need to radiograph to assess bone loss.

For more on how gingival over growth will affect probing depth, review this paper:

[http://www.toothvet.ca/PDFfiles/gingival\\_hyperplasia.pdf](http://www.toothvet.ca/PDFfiles/gingival_hyperplasia.pdf)

Since cats are far less variable in size, normal probing depths are more consistent. Around most feline teeth I do not like to find probing depths of more than 0.5 millimeters. Around the canine teeth, I will accept a probing depth of up to 2 millimeters if other parameters are normal.