

Enamel Hypoplasia

Useful background review for this subject can be found at:

<http://www.toothvet.ca/PDFfiles/tooth.pdf>

<http://www.toothvet.ca/PDFfiles/endo.pdf>

Enamel is the hardest tissue in the mammalian body, composed of crystals of hydroxyapatite arranged in prisms roughly perpendicular to the junction with the underlying dentin. The closely packed crystals occupy 88% of the volume of the enamel, the remaining 12% being water and organic material. By weight, enamel is 96% mineral. It is acellular and considered non-living. As enamel is relatively non-porous and impervious it acts as an effective barrier to prevent bacteria in the oral cavity from reaching the pulp tissues inside the tooth.

Enamel is formed by ameloblasts during tooth development. Amelogenesis stops prior to tooth eruption and no more enamel is produced. Once the tooth has erupted into the oral cavity, enamel can be lost gradually (or rapidly if the animal has a chewing vice) to chemical and mechanical forces. Once the tooth is visible in the mouth it has no way to produce, replace or repair lost or damaged enamel.

Enamel is not produced over the entire crown all at once. There are various stages of amelogenesis which start at the tip of the crown and work their way progressively down the crown to the cemento-enamel junction. At any given moment, there are different stages underway at different locations on the crown. I visualize this sort of like how the railway was built across Canada.

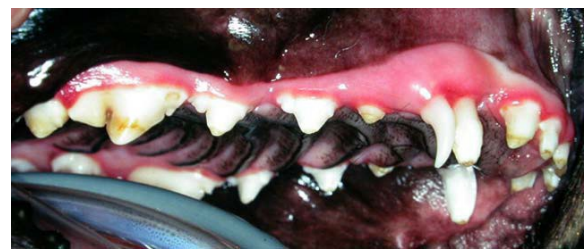At the front of the process were the surveyors plotting the course across the land. Behind them came the engineers to cut a path through forests and mountains. Behind them were the graders, creating a smooth bed of packed gravel, then a crew to lay down the ties, then the crew to lay and secure the rails. Picture this chain of crews moving sequentially across the land. The success of the entire project relied on each crew doing its job well so that the crew that followed could do theirs.

If the crew laying the gravel bed had a few days when they were off their game and they did not

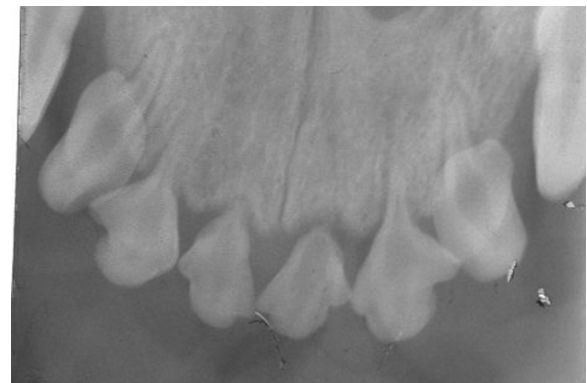get the bed packed densely enough but they kept advancing nonetheless, they would leave a section of poor-quality gravel bed behind them. Along comes the tie crew and the rail crew and all looks fine but when the locomotive runs over the track in this bad section, the bed below the rails crumbles and the train derailed. With people building a railway, crews could be recalled to repair the defective section and the finished product would be fine.

In the case of amelogenesis, it is not different cells doing different jobs, but the same cells at different stages of maturation doing the different jobs. First they lay down the organic matrix and then they lay down the hydroxyapatite crystals within this matrix and finally they become quiescent and vestigial. Once the cells have matured from one phase and moved to the next, they cannot go back and fix any defects.

Anything that disrupts the delicate ameloblasts during enamel production will result in defective enamel which may be very porous and weak. This defective enamel is often present at eruption



The right maxilla of a dog with generalized enamel hypoplasia and a persistent primary maxillary canine tooth.



Radiograph of this same patient showing severe hypoplasia of the roots of the maxillary incisors. All teeth were affected to some degree and most required extraction.

but will soon be lost to abrasive forces. This leaves an area of exposed dentin and rough margins to the surrounding enamel. In some instances the enamel does not form at all and so is missing as soon as the tooth erupts.

Enamel hypoplasia, as it is commonly known, may affect a single tooth if the insult is localized (e.g., infection from a fractured deciduous tooth, iatrogenic from inelegant deciduous tooth extraction, bruising from local facial trauma). Many systemic conditions, such as pyrexia, hypoproteinemia, epitheliotrophic virus infection can cause widespread enamel hypoplasia on those areas of many teeth that were undergoing amelogenesis during the time of the illness. A serious systemic illness may also cause hypoplasia of the root structure of the permanent teeth. I have seen dogs who had severe hypoplasia of most roots with some incisors having no roots at all.

With generalized enamel hypoplasia, the enamel produced before the insult will be normal and the enamel produced after the insult has passed will be normal, but the enamel that is under production during the insult will be defective. This explains why in many cases of generalized enamel hypoplasia there is a band of defective enamel that runs across the crowns of many teeth. This may be at the tips of the crowns, mid crown or near the gum line depending on the timing of the insult.

With localized enamel hypoplasia, the location of the lesions is determined by the location of the trauma and may be isolated to a small portion of the crown of just one tooth or may involve larger portions of a few adjacent teeth.

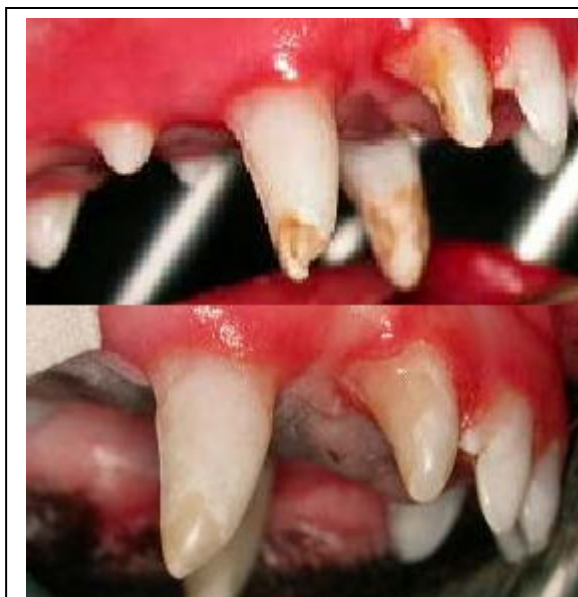Under the defective or missing enamel is dentin, which eventually makes up the bulk of the tooth. It is about as hard as bone but much softer than enamel. It is pale yellow in colour, compared to the stark white of normal enamel. Dentin is roughly 72% mineral, 18% organic matter (mostly collagen) and 10% water by weight.

Dentin is arranged as a collection of tubules running from the pulp towards the enamel. The tubules are roughly 4µm in diameter near the pulp and narrow to 1µm near the enamel.


Lining the inner aspect of the dentin wall is a layer of cells known as odontoblasts. These cells extend cytoplasmic extensions into the lumens of the tubules running all the way out to the enamel, therefore, dentin is considered a living tissue. In some of the tubules, unmyelinated nerve fibers lie alongside the odontoblastic processes and so dentin is a sensitive tissue that can detect heat, cold, touch and variations in osmotic pressure with all stimuli being perceived as pain.

Dentin is produced by the odontoblasts on the inside of the tooth throughout the life of the tooth so as the tooth matures, the dentin wall becomes thicker and the pulp chamber smaller.

A tooth that erupts with defective enamel that soon falls away has exposed dentin, which is sensitive and porous and so a potential pathway for bacteria to gain access to the pulp to cause a septic pulp necrosis. These freshly erupted teeth are immature, with thin dentin walls and wider dentin tubules than a mature tooth, and so they are at their most vulnerable at this phase. Therefore, early intervention (as soon as the



The localized enamel hypoplasia in this young dog was caused by inappropriate primary tooth extraction. The second photograph is of the right upper third incisor and canine teeth following removal of more defective enamel and restoration with a bonded composite resin.



Radiograph of the right lower canine tooth of a 6-month-old dog showing how thin the dentin wall is at this stage of development.

attended enough lectures and wet-labs on restorative dentistry you will be familiar with the materials and will not need my advice on which ones to use.

problem is detected) is indicated.

Diagnosis and assessment must always precede treatment planning. This begins with a thorough examination under general anesthesia to document all areas of coronal defects as well as whole-mouth intra-oral dental radiographs to look for problems with root development.

In considering treatment options (extraction, dentin bonding, composite restoration, cast metal restorations) a number of factors need to be considered including:

- number of teeth affected
- location of defects (crown tip, mid crown...)
- importance of teeth affected
- severity of defects (coronal and root)
- owner's expectations and resources
- operator's knowledge, skills and resources

Each case needs to be considered on its own merits in order to develop an appropriate short and long-term treatment plan. The objective is to provide the patient with a mouth free from pain and infection. In cases of severe coronal and root defects, this may necessitate whole-mouth extraction. In cases of small coronal defects it may simply involve removing further defective enamel and coating the crown with a fluoride-releasing bonded resin to seal the dentin tubules, decrease sensitivity, offer protection for the underlying pulp and to help strengthen the remaining enamel. These procedures are technique sensitive and are [NFCO](#). Therefore, I will not be providing advice on what materials to use. If you have to ask, it indicates that you have not taken enough continuing education to be offering these services. By the time you have