

WHOLE MOUTH EXTRACTION FROM THE OTHER SIDE OF THE TABLE

Three years ago, I wrote a lengthy essay on whole-mouth extraction (WME) and why it might actually be good to remove all dog and cat teeth at six months of age. I was being a bit facetious to make a point but there is some logical validity to the notion. Have a look - [WME for all](#).

As I write this (on January 27, 2019), I have been back at work for a total of eighteen days. In that time, I have done sixteen whole-mouth extractions (I did three on January 2, to kick the year off). Most of the owners of these pets arrived well prepared by their primary care veterinarian for this. They understood what I was going to be doing and why, which is great. But for many pet owners, hearing that their pet needs to have all of its teeth removed can come as a really nasty shock and many owners may simply decline that treatment outright. Therefore, I want to offer some thoughts for primary care veterinarians to share with their clients to help them make an informed decision regarding WME.

[addendum in January 2020. In 2019, we did a total of 60 whole-mouth extractions in dogs and 69 in cats. Here is a facebook post about that - [facebook post WME](#). The pie charts from that post can be seen on page 4]

The Prime Directive



Among the first things I tell clients when we meet is that my objective is not to save teeth. My prime directive is to provide my patients with a mouth free of pain and infection. Sometimes that

means treating teeth to return them to health and preserve their form and function. Sometimes it means extracting diseased teeth.

The next thing I tell clients is that, in the vast majority of cases, domestic pet dogs and cats do not need teeth. They do not have to hunt and kill their own food, they do not have to chew raw meat from a carcass, they do not have to defend their territory or protect themselves from predation. They have their owners to take care of all of those needs for them. Food is already dead and in the bowl, ready to swallow and there are walls, a roof and fences for protection.

Owners will often ask “How will [pet name] manage without teeth?” to which I answer, “They do far better with no teeth than they do with bad teeth.”

Dental Pain

So much of the dental disease I treat is very painful, yet owners are often unaware that their pet is in pain (and often has been for months if not years). How can this be? Have a look at Myth #1 in this paper - [mythology](#). Dogs and cats are masters of masking their pain and carrying on as if all is fine. But once we take away the source of the pain the improvement can be very dramatic.

A colleague once told me the story of her grandmother who had apparently suffered from headaches her entire adult life, but she was unaware of her own suffering because it was a constant. It was her normal and as far as she knew, everyone else felt the same. Then, in her later years, she was put on a medication for some cardiac condition. An unexpected side effect was that the headaches went away. It was only after the pain was gone that she became aware of what she had been enduring all those years. I think the same phenomenon applies to dogs and cats with dental disease. Much dental disease comes on slowly, becomes the “new normal” and life goes on.

Why do so many pets need WME?

One might wonder why I have had to do so many WMEs recently. Keep in mind that I am a referral specialty practice, so I do see a skewed population (cases the primary care veterinarian

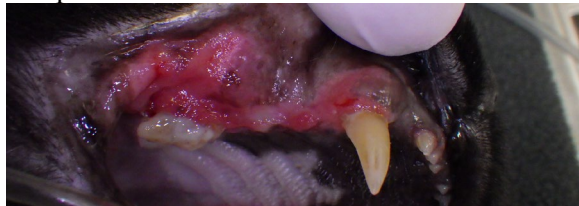is uncomfortable managing – the worst of the worse). While 16 WMEs in 18 days is a bit out of the ordinary, it is not far off our typical case load. We do a LOT of WMEs, week in and week out, all year long.

In many cases, it comes down to being reactive rather than pro-active with oral care. I talk more about that here - [PerioCommon](#). Since most significant dental disease is going on below the gum line, hidden from view, if you wait until there are visible signs of disease, you have probably waited far too long ([PerioAgain](#)).

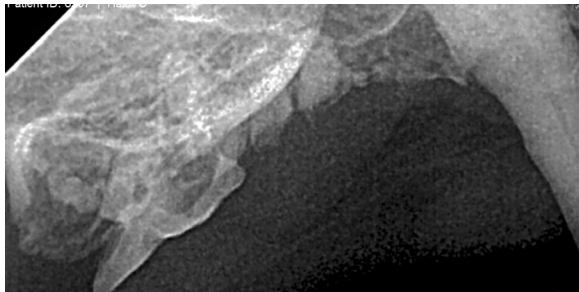
The table below lists who had WME and the reasons why (the disease processes involved that necessitated extraction). In the legend below the table you will see links to papers describing some of the conditions.

I do not have a link to papers on retained root tips or oronasal fistulae so I will briefly describe them here.

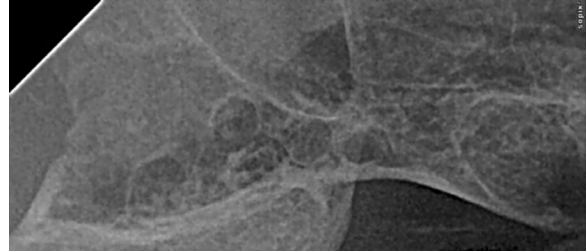
Retained root tips refers to a situation in which the crown of the tooth is absent, but remnants of its root(s) remain in place. This can happen if the crown breaks off leaving the root behind. It can also arise as a result of incomplete extraction (someone leaving a root remnant behind). This second situation can be completely prevented by always taking post-extraction radiographs to confirm and document that all extractions are complete.



This clinical photograph suggests that the right upper 3rd premolar is missing but until we get intra-oral dental radiographs we cannot know for certain.

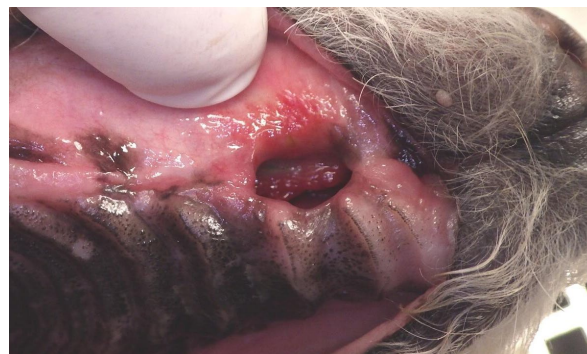

The radiograph shows that, while the crown of the 3rd premolar is absent, the roots are still very much present and in need of extraction. There is also extensive type 1 resorption of the 4th premolar.



And this post-operative radiograph (occlusal view) confirms the complete removal of the teeth/roots.

An oronasal fistulae is quite literally a hole that goes from the mouth into the nasal passage. The layer of bone between the roots of some of the upper teeth and the nasal passage is quite thin. If there is chronic periodontal disease affecting these teeth, the resulting tissue destruction can erode through the bone creating an oronasal communication. These holes are not readily visible while the tooth is in place (partially plugging the hole) but becomes much more evident when the tooth is absent. The most common sites for oronasal fistulae would be on the palatal side of the upper canine teeth, around the palatal root of the upper 4th premolar teeth and around any roots of the other upper premolar teeth.



This photo is of a 10.5-year-old miniature poodle with a large oronasal fistula where the right upper canine tooth had once been. The primary care veterinarian had attempted to close this defect twice. They can be very frustrating to manage.

This chart offers some information of the sixteen animals who had whole-mouth extraction in January of 2019

Species	Breed	Age	Reason
Cat	DSH	2 yr	PD, TR, FIV+ve
Cat	Siamese	6 yrs	PD, TR
Cat	DSH	6 yrs	PD, TR, RRTs
Cat	DSH	11 yrs	PD, TR, RRTs
Cat	DSH	8 yrs	FCGS, PD, TR, RRTs
Cat	DSH	1.5 yrs	PD, TR, RRTs, deformed teeth
Cat	DSH	5 yrs	PD, TR, RRTs
Cat	DSH	5 yrs	CCF 104, PD, TR
Cat	DLH	11 yrs	TR
Dog	Dachshund	14 yrs	PD, TR, ONFs
Dog	Toy poodle	10 yrs	PD, ONFs
Dog	Shih tzu	11 yrs	PD, ONFs
Dog	Chihuahua	10 yrs	PD, ONFs
Dog	Dachshund	12 yrs	PD, TR, RRTs,
Dog	Cocker spaniel	11 yrs	PD, ONFs
Dog	Dachshund	13 yrs	PD, TR

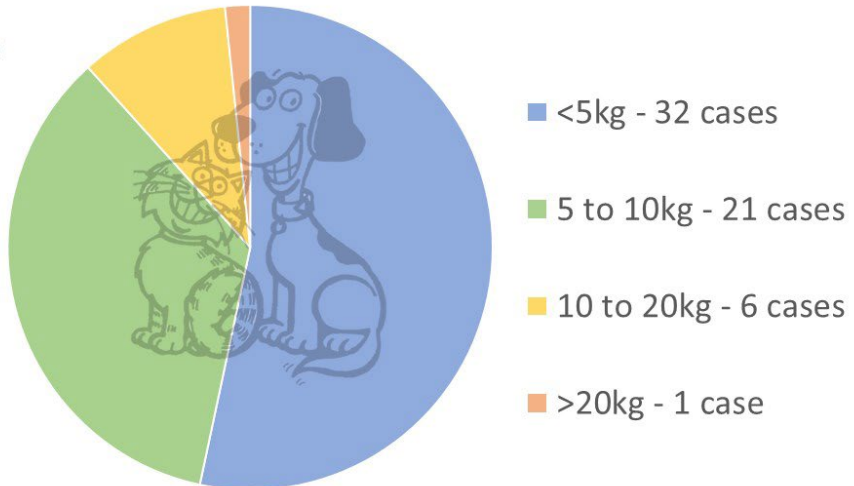
PD = [periodontal disease](#); TR = tooth resorption [cat](#) and [dog](#); ONF = oronasal fistula; RRT = retained root tips; FCGS = [feline chronic gingivostomatitis](#)

These pie charts offer some information on the 129 animals who had whole mouth extraction through all of 2019. For the 60 dogs, we see which breeds were more commonly treated and the distribution of body weight. As you can see, the vast majority of whole-mouth extractions in dogs were done in small dogs (under 10 kg) with the very small dogs (under 5 kg) making up more than 50% of the total.

Hale Veterinary Clinic 2019 Whole Mouth Extraction Cases Dogs (60 cases)

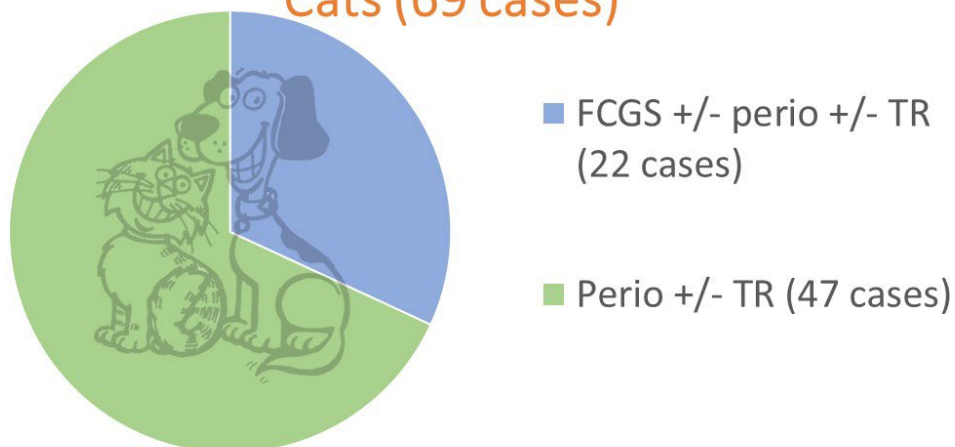
Most common breeds

- Yorkie
- Chihuahua
- Toy poodle
- Shih Tzu
- Dachshund



For the cats the chart is comparing how many had periodontal and tooth resorption versus how many had that as well as feline chronic gingivostomatitis.

Hale Veterinary Clinic 2019 Whole Mouth Extraction Cases Cats (69 cases)



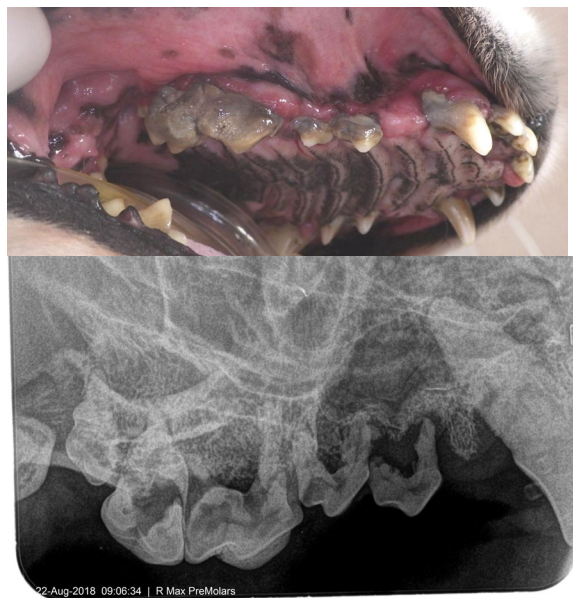
What To Expect: Result may vary

I am no fan of testimonials and I typically cringe when I see them on clinic websites. For one thing, they are too easy to fake. For another, one person's opinion is not a scientific study and is very low-level evidence (virtually irrelevant).

On the other hand, we make a lot of our major decisions based as much or more on our emotions than our intellect. Many clients are not interested in reading dry scientific papers full of statistical analysis. They want to know what their friend and neighbours think and what others in similar circumstances have experienced. Therefore, I am going to share some of the comments and feedback we have received here at Hale Veterinary Clinic. I will add that this feedback is typical of that received by other practitioners who are providing appropriate oral care for their patients.

I should mention that results may vary. Some animals have an incredible improvement in quality of life. For others, the results may be subtler. For the occasional few, the response may be disappointing (most commonly in cats who have suffered with [feline chronic gingivostomatitis](#) for a long time prior to extraction). There are no guarantees other than that for many of these animals, they have no hope for lasting and meaningful relief without whole-mouth extraction.

Case #1; a 10-year-old cocker spaniel seen in August of 2018. The dog had had no prior dental treatment. On presentation there was end-stage periodontal disease of virtually every tooth. I did whole-mouth extraction. This month the referring veterinarian called to say that they had seen the dog for its annual wellness examination and vaccinations. The owners reported that the dog is "like a puppy again" and that the whole-mouth extraction was "the best thing ever".

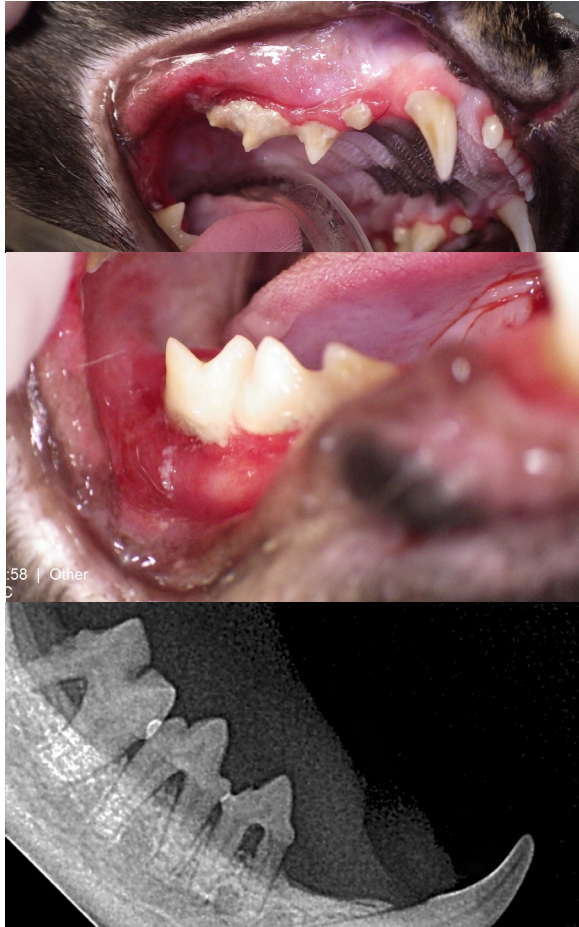


A few images of Case #1, the 10-year-old cocker spaniel. These images are the pre-operative photograph and radiograph of the right upper jaw.

Case #2; In December of 2018 I treated a 1.5-year-old cat who had dramatic generalized gingivitis, stomatitis and periodontitis (yes, already at under two-years of age). I did whole-mouth extraction and with the owner's permission will share a portion of an email she sent me one month later.

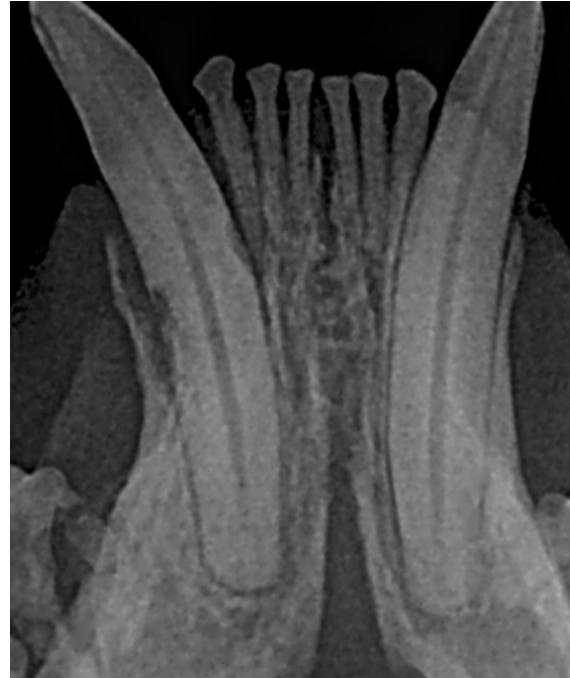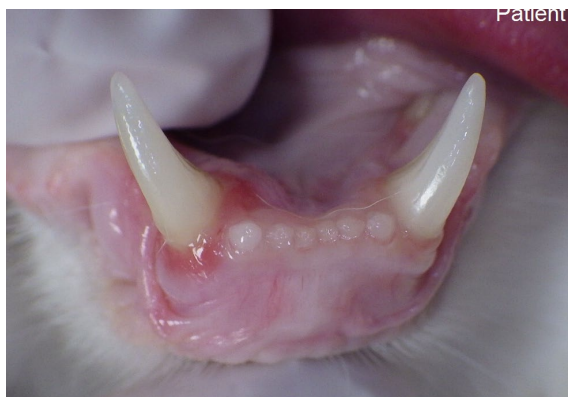I have been a pet owner my whole adult life and have never been faced with this kind of decision before. There are many factors at play, but I think with the guidance I received from all the professionals involved the right choice was made. [REDACTED] did exceptionally well the days following surgery - in fact, it was difficult to tell that she had had surgery at all! She is now even more playful and happy and is even putting on some much-needed weight now that she can eat!! We will continue to watch over her for any signs of trouble but in the meantime, we will give her lots of love!!

Many thanks to all involved. It was a difficult time but has turned out to be very rewarding.

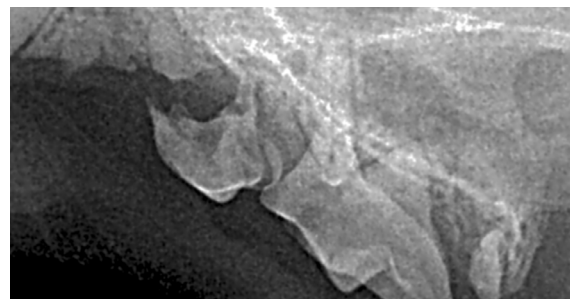
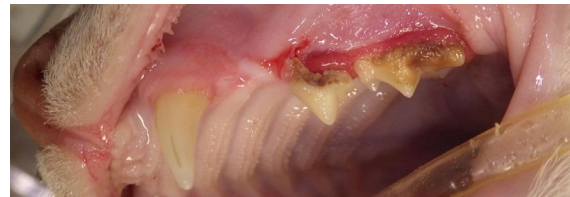

Some of the pre-operative images of case #2.

Case #3. A six-year-old Siamese with lots of periodontal disease and tooth resorption was presented early this year for whole-mouth extraction. Two weeks later when I saw him to assess healing his owners reported that he was now “play-fighting” with his brother a lot more and so his owner took that to mean that he is feeling much better than he has in a long time.



While the pre-operative photograph of the rostral mandible of case #3 revealed some inflamed gingiva around the right lower canine tooth, the visual presentation did not do justice to the degree of disease. In the radiograph of the area we can see a deep infra-bony pocket and root resorption (type 1 tooth resorption) affecting the lower right canine tooth necessitating its extraction.



Again, the clinical photograph did not do justice to the degree of pathology going on below the surface. The radiograph shows that the mesial root of the 3rd premolar has been completely severed from the rest of the tooth due to chronic inflammation (type 1 tooth resorption again).

As I mentioned, these three cases are not unique. We have an album full of thank-you notes from owner's whose pets have experienced great improvement following whole-mouth extraction and I am sure every veterinary dentist and many general practitioners could tell you the same thing.

Dominoes and Probabilities

Some patients arrive with end-stage disease of all remaining teeth and so there is no option whatsoever other than whole-mouth extraction. For others, whole-mouth extraction is indicated even when some teeth are relatively healthy. For example, there are some domino effects in which the extraction of one tooth predicates the extraction of another.

When a cat loses an upper canine tooth, there is a real tendency for the upper lip to sag inward. This often results in the lower canine causing trauma to the upper lip as outlined in this paper - [lip entrapment](#). Therefore, in cats particularly, when an upper canine tooth is lost it is prudent to pro-actively remove that risk. Options include crown reduction and endodontic therapy or extraction of the lower canine tooth.

Also in cats, when they lose the lower molar, it is common for the upper 4th premolar to traumatize the mandible, resulting in a proliferative soft-tissue lesion as outlined in this paper - [Feline Gum Chewer](#). Without the lower molar, the upper 4th premolar and molar are functionally useless and are prone to causing painful traumatic lesions, so when the lower molar in a cat is lost, it is prudent to also remove the upper molar and 4th premolar teeth.

And then there are probabilities to be considered. If a patient has developed advanced disease of several teeth (periodontal disease and/or tooth resorption) what are the chances of any teeth left in remaining healthy.

We know (basically) what causes periodontal disease and in some cases the causes/risks can be managed better in the future than they have been in the past such that teeth left in place might have a reasonable chance of staying healthy, but that is not always the case. If an owner has already been doing all the right things to try to prevent periodontal disease and trouble arose

anyway, then the prognosis for any teeth left in place would be suspect at best.

With most tooth resorption, since we do not know the cause(s), we can do nothing to prevent further lesions. What we do know is that dogs and cats that have had some tooth resorption are likely to develop more in time.

This paper discusses some of the issues to consider when trying to decide whether to treat or extract a tooth - [treat or extract](#). This paper talks about "cleaning house" in the geriatric patient to obviate the need of any further dental treatments in a pet who may already be or may be on the way to becoming a poor anesthetic risk - [CleaningHouse](#).

I would say that I do not make the recommendation of whole-mouth extraction lightly. I make it commonly because of the level of disease so often present in animals that are referred to me. For most cases, my approach is as follows:

- get the patient under general anesthetic and stable
- do a detailed clinical and intra-oral dental radiographic examination
- catalogue all the teeth that require extraction
- add to the list those teeth that should go because of domino effects
- for the remaining teeth, ask the question "what benefit will they provide to the patient balanced against the liability they pose for the animal's future oral health?"
- discuss the findings with the owner to decide together how to proceed and to get informed owner consent to carry out the plan.

When presented with the reality of what would be necessary to try to maintain oral health with teeth in the mouth, many owners opt for a one-and-done approach so their pet can live with a mouth free of pain and infection for the rest of its days.