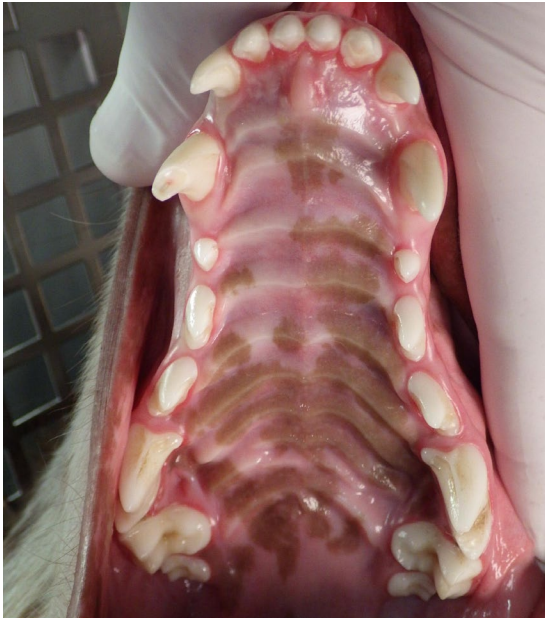
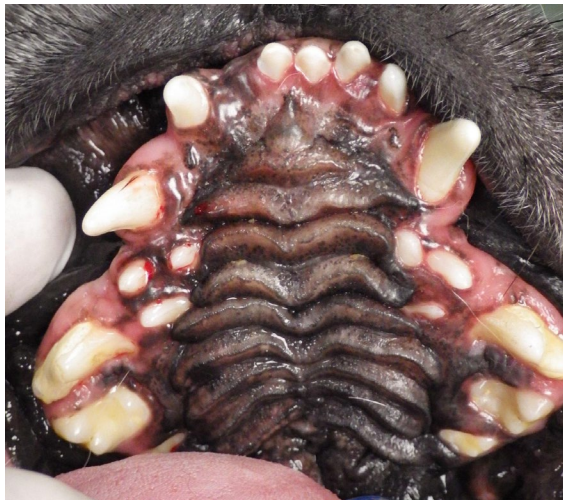
WHY DO I SAY “STOP BRACHYCEPHALISM, NOW!”?



Australian Shepherd with a fractured tooth but beautiful (and healthy) anatomy. (6533)



A pug. Need I say more? (6500)

There are so many reasons to stop breeding brachycephalic dogs and cats (both pure bred and mixed breeds). I am going to focus on the oral health issues. There are many more problems built into these animals, but I deal with the oral cavity and so that is what I will discuss here.

Where do all the images in my articles come from? Unless specifically indicated otherwise, these images are all from cases I have seen and treated personally in my referral practice.

BRACHYCEPHALIC DENTAL/ORAL ISSUES

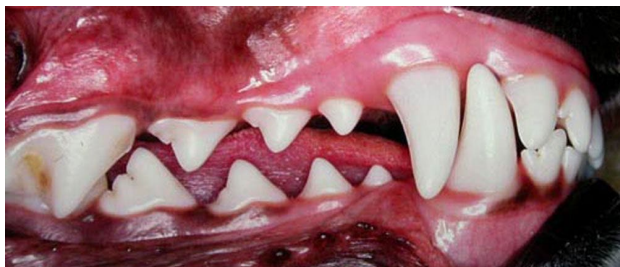The issues I see specifically and very commonly in brachycephalic dogs include:

- abnormal tooth-to-tooth and tooth-to-soft tissue contacts causing trauma to hard and soft tissues and sometimes pulp necrosis in teeth
- caudal buccal traumatic granulomas (from abnormal contacts)
- crowding and rotation of teeth predisposing to periodontal disease.
- under-erupted teeth predisposing to pericoronitis.
- un-erupted teeth predisposing to dentigerous cyst formation.
- fur entrapment in deep palatal fold and grooves.
- wide, loose symphysis

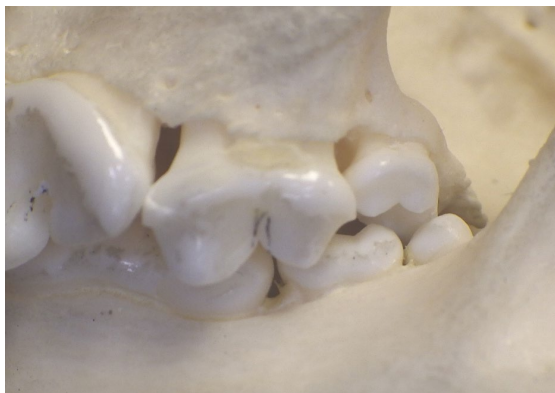Not every brachycephalic dog has all of these problems, but virtually all have some of them. These problems are not restricted to brachycephalic breeds, but they are much more common in that population. Brachycephalic cats may also be affected by some of these, but generally to a lesser degree (<http://petsinthecitymagazine.com/wellness/2016/health-concerns-for-brachycephalic-cats>). Now let's look at each problem in more detail.

Abnormal Occlusal Contacts

Virtually all brachycephalic dogs have a class III malocclusion (upper jaw too short) – they are selectively bred specifically to be built this way and it is usually in their breed standard that they must have this serious craniofacial deformity (“defective by design” or “mandated deformity”). First here is a photo of a young dog with proper occlusion. My heart sings when I see a mouth like this.

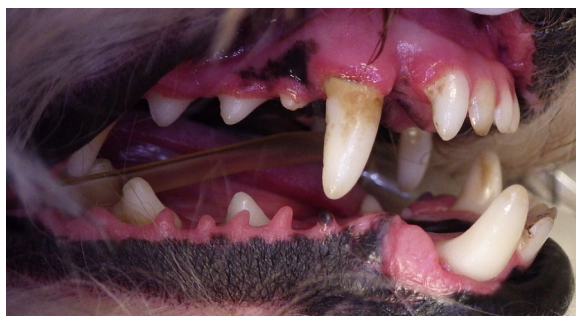

The only place in a dog's mouth that there is supposed to be any tooth-to-tooth contact is the two upper molars occluding against the distal 1/3 of the lower first molar and the second and third lower molars. Any tooth-to-tooth contact elsewhere in the mouth is abnormal and undesirable. As with many things, there are degrees of abnormality. In some instance the tooth-to-tooth contact is minor enough and at an angle such that no intervention is indicated. Other times, selective extraction of one tooth or the other (removing either the hammer or the anvil) to alleviate the traumatic contacts is indicated. Sometimes [crown reduction and vital pulp therapy](#) are indicated.



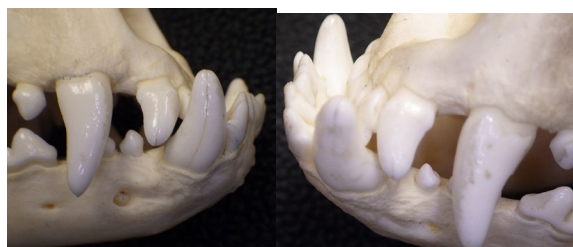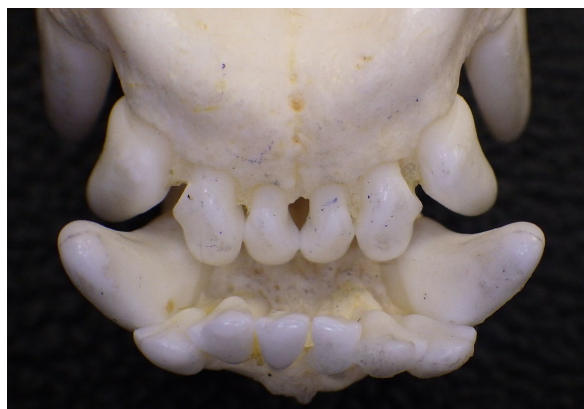Showing how the upper two molars are supposed to contact the lower three molars. This is the ONLY place in a dog's mouth that there should be any tooth-to-tooth contact.

And now a shih-poo. This makes me sad.



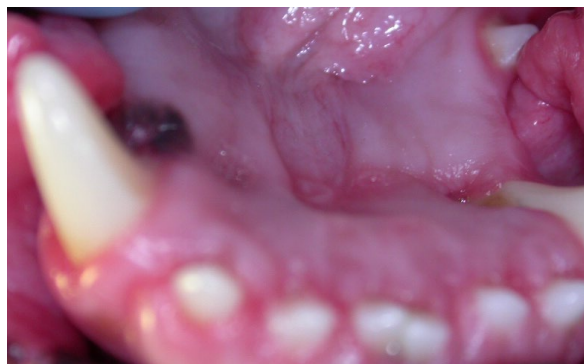6756

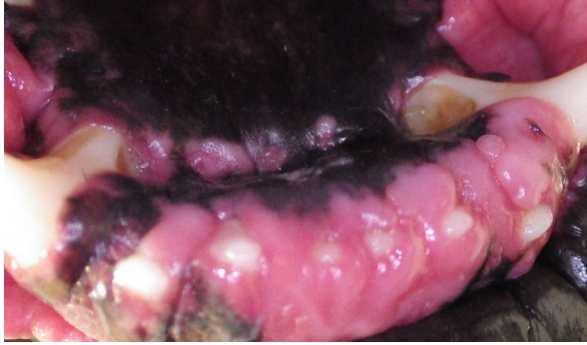If we strip away the fur and soft tissues, we would see something like this.



In almost all dogs with a class III malocclusion, there are abnormal tooth-to-tooth and/or tooth-to-soft tissue contacts and neither of these situations are cute, comfortable or benign for the dog.

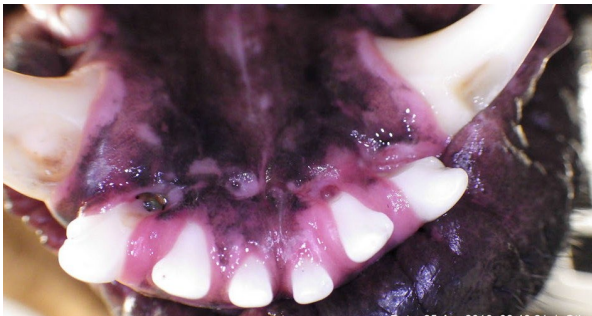In the next two photos of a boxer (and by the way, I have another paper just about [boxer oral issues](#)) we can see irritated contact points in the oral mucosa on the floor of the mouth where the upper incisors contact. We can also see gingival recession and attrition (wear from tooth-to-tooth contact) on the lingual aspect of the lower canine teeth. The upper incisors have literally (and I use that term correctly) been grinding away at the lower canine teeth since the adult teeth erupted.





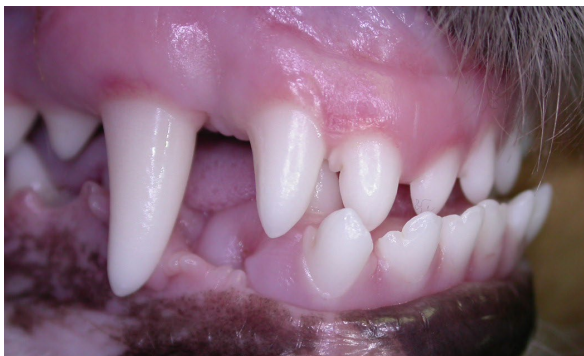While abnormal occlusal contacts may seem a relatively insignificant problem, imagine spending your life walking around with a pebble in your shoe. You could do it, but you would rather not have too. Removing this constant irritant would improve your quality of life.

Here are images from a Mastiff for whom this was causing several significant problems.

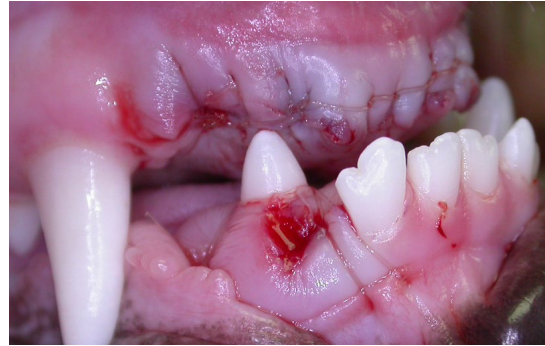

A more detailed photo essay of this case can be seen here - [Mastiff MAL3](#).

In this next case, the class III malocclusion was causing the eruption of the lower canines to be prevented by their contact with the palatal aspect of the upper incisors and the upper incisors were in traumatic contact with the mandibular structures. We need those lower canines to erupt fully or we will get [pericoronitis](#).



Treatment involved extraction of all upper incisors and the lower 3rd incisors. Now the dog can close its mouth without biting itself AND there is no mechanical interference with the eruption of the lower canine. **NOTE** – this is a time sensitive problem. If we want those lower canines to erupt, we must perform the appropriate extraction at an early age while the teeth still have the potential to erupt (by seven months of age if at all possible).

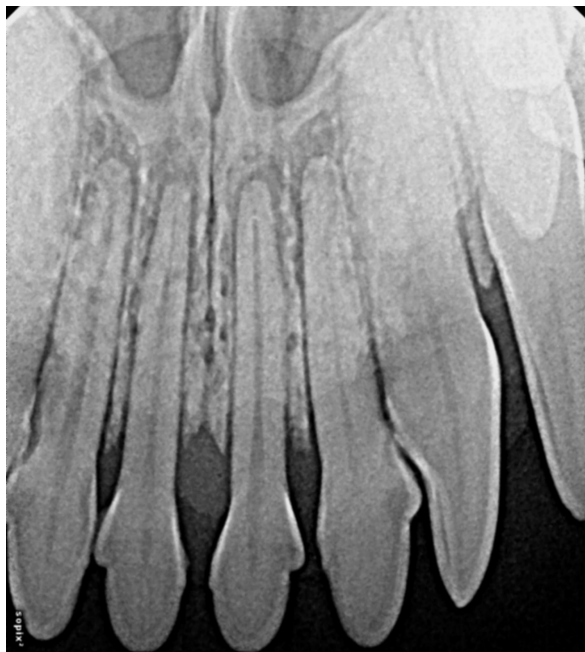


Some owners (and veterinarians) are reluctant to extract what they perceive to be healthy teeth. Keep in mind that in a class III malocclusion, the upper incisors have become functionally useless AND they are causing problems. Get them the heck out of the mouth. We are not about saving teeth. The goal always is to optimize oral health and comfort. In deformed mouths, this will almost always mean removing healthy teeth, in a pro-active fashion to make the best of a bad design.

So far I have focused on how the upper incisors cause problems with the mandibular structure, but that is only one side of it. It is not at all uncommon for me to find evidence of pulp necrosis in the maxillary incisor teeth of dogs with class III malocclusion. The evidence is typically coronal discoloration and/or larger than normal pulp chambers in the affected teeth. For more on the diagnosis of endodontic disease, I would refer you to [this paper](#).

The mature pug in the following image had so much oral pathology because of its distorted anatomy, that I ended up doing whole-mouth extraction (it is not at all uncommon for small brachycephalic dogs to require this). Based on the pulp chamber sizes in the upper incisors, I deemed that three of the six had suffered pulp

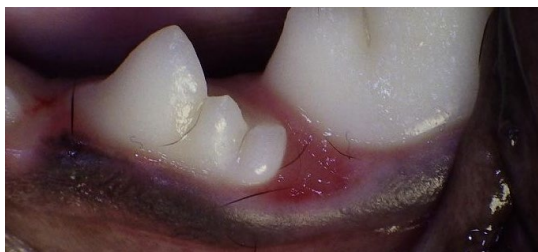necrosis a long time before the radiograph was taken.




My theory as to why these teeth undergo pulp necrosis is that the constant concussive trauma of these teeth bashing into the lingual aspect of the lower incisors incites a traumatic pulpitis which eventually kills the pulp. I have experienced a traumatic pulpitis in one of my own lower incisors. I would not wish this on anyone.

There should be no tooth-to-soft tissue contact anywhere in a dog's mouth. Again, there are matters of degree, but imagine biting yourself every time you close your mouth. Not a pleasant prospect.

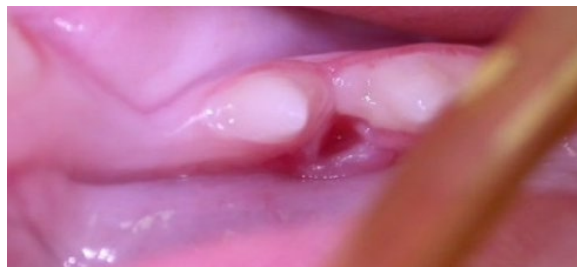The next image is of a 6-month-old pug. On both sides of his mouth, his upper 4th premolar teeth (teeth 108 and 208) were in traumatic contact with the soft tissue just in front of his lower 1st molar teeth (409 and 309). This photo is of the left side showing where 208 was causing a traumatic, ulcerated lesion in front of tooth 309.



And abnormal occlusal contacts do not just affect dogs. Here is a seriously deformed cat.



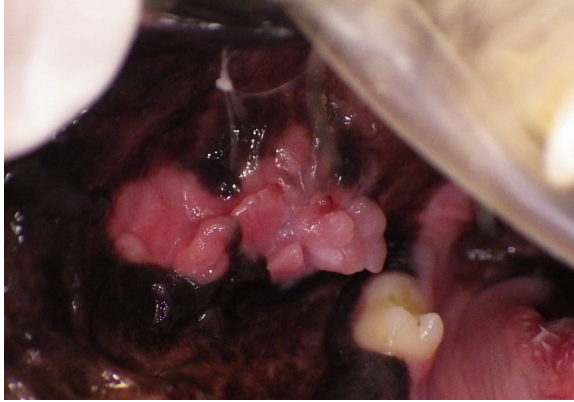Not only is the maxilla severely shortened, it is also asymmetric, twisted to the right. As a result, the right upper canine was digging into the right mandible on the tongue side of the lower premolars.



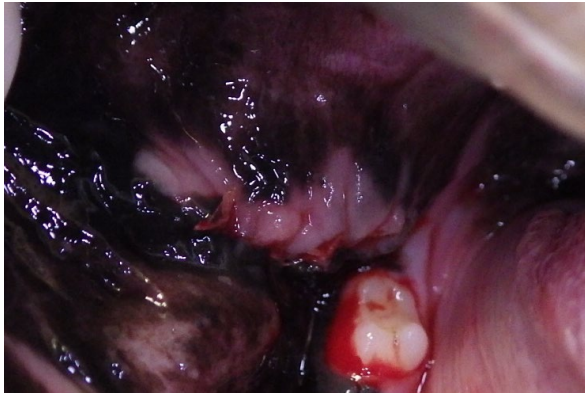
Caudal Buccal Traumatic Granulomas

Often with brachycephalic dogs (of any size) the cheeks are very tight to the head and as a result it is close to impossible for some to close their mouths without biting their cheek lining (the inside of the cheek is known as the buccal surface). This results in trauma to the buccal mucosa, which becomes inflamed and enlarged, making it even harder for the dog to avoid biting it some more. Most of us have had experience biting the inside of our cheek at some time and it hurts. Imagine living with this every day of your life. Here is a photo of an older shih tzu with significant caudal buccal traumatic granulomas on the right side.

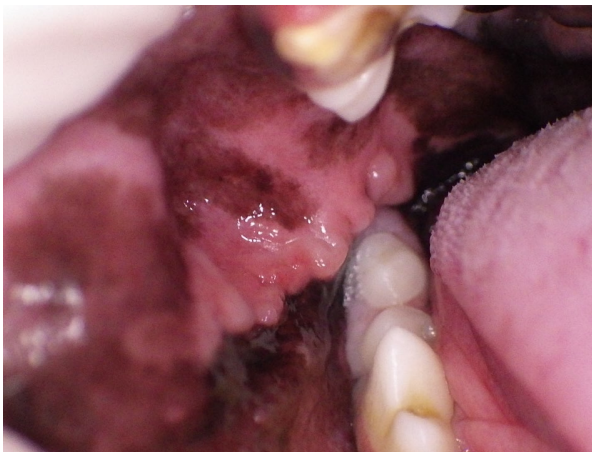
A brachycephalic mouth has a lot of problems. It is hard to discuss any of these problems in isolation because there is a lot of interaction of the structures, so this does jump around a bit.



In this case, I resected the excess tissue and sutured. Hopefully that will do the trick for this 13-year-old dog.



This one-and-half-year-old Brussels Griffon (next image) had already developed some significant lesions. She was missing her upper 4th premolar and had an under-erupted 2nd molar so I just removed both upper molars (the hammers) so that she can closer her mouth without traumatizing this tissue further. The problem, as usual, was bilateral and so required the same approach on both sides of her mouth.

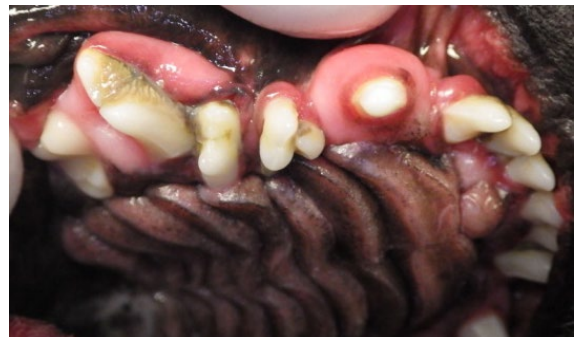

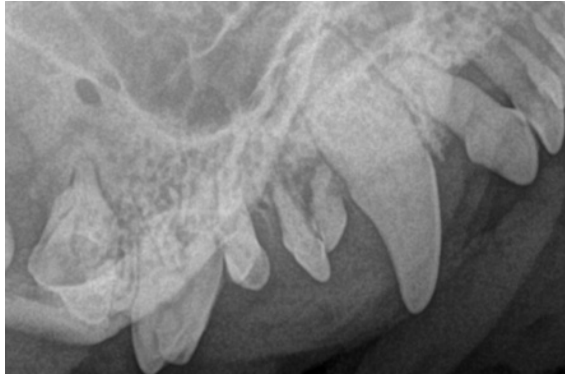To alleviate these traumatic contacts (in dogs and cats), it is usually necessary to extract teeth. Sometimes we have to ask ourselves, which tooth (teeth) should be removed? The answer is based on a number of criteria. I always try to sacrifice less important teeth to improve the prognosis for more important teeth. I try to preserve as much form and function as is reasonable. And we must always consider that as we remove some teeth, we may allow the mouth to close further so that now more teeth may come into abnormal contacts. Each mouth is managed on its own merits with a careful assessment of the live patient in three dimension.

Dental Crowding and Rotation

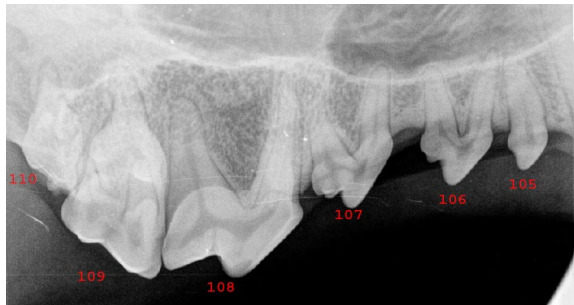A dog is supposed to have 20 upper teeth; 10 per side (three incisors, one canine, four premolars and two molars). These teeth are supposed to be proportioned and spaced as in the “good” examples I have shared above. Brachycephalic breeds (and mixes) have been selectively bred to have deformed heads with upper jaws far too short to accommodate all 20 with proper spacing and alignment. To understand the impact this has on oral health, you might want to review [this paper](#) on periodontal anatomy and physiology.

The following images are of a typical pug. In the photo of the right maxilla (upper jaw), we see that the 2nd and 3rd premolars are rotated 90 degrees to fit in. Then there is no space (no gum tissue) between the 1st and 2nd premolars or between the 3rd and 4th premolars. This was foot-in-the-door for periodontal disease to affect all four of these teeth. And the radiograph that follows the photo shows the dramatic bone loss around those roots. For pet owners reading this, that is the result of hidden infection effectively rotting away the bone around the tooth roots ([perio_hidden.pdf](#)).



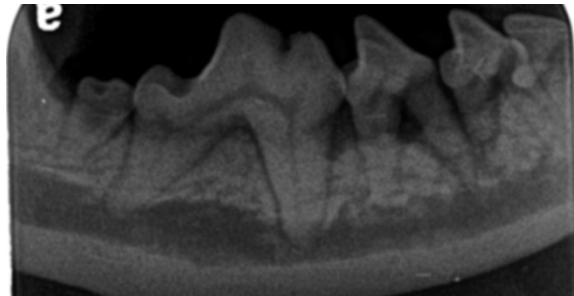
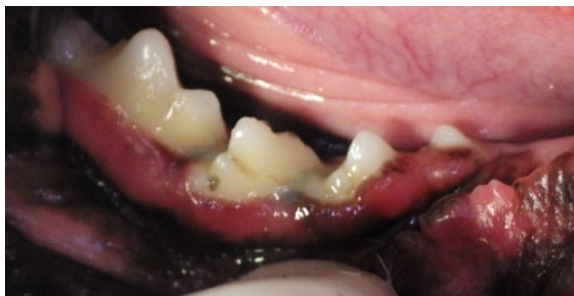

What does a radiograph of a normal and healthy right maxilla look like? Like this:

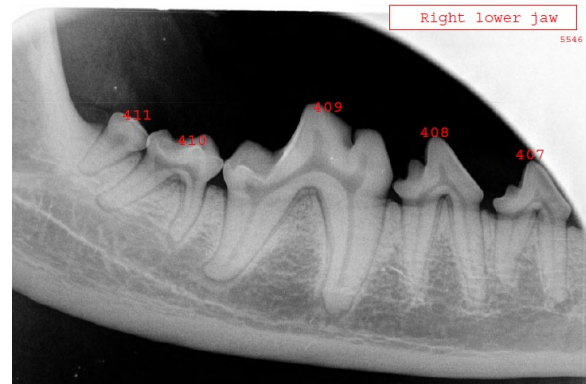


For a complete set of normal intra-oral dental radiographs of a dog with a proper head click [normal_canine_rads.pdf](#).

And it is not just the upper jaw that is too short. Often the lower jaws are as well, though to a lesser degree. This also leads to crowding and an increased risk for periodontal disease as in this same pug.



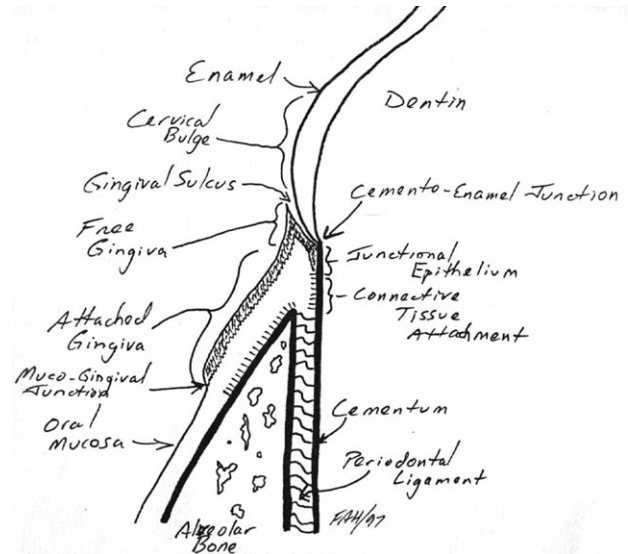
And here is an example of a good, healthy right mandible:



The only way to deal with these crowding issues is through selective extraction, removing less important teeth to alleviate the crowding and improve the prognosis for more important teeth. Again this should be done at an early age as a pro-active measure. [This paper](#) illustrates how being proactive can benefit your patients.

Under-eruption and Pericoronitis

I have [another paper](#) just on this problem and so I will only discuss it briefly here. This brevity does not mean that it is an unimportant problem.



My drawing above shows the proper relationship between the tooth and the surrounding periodontal tissues. If the tooth has erupted properly, the cemento-enamel junction is above the top of the bony socket. Periodontal ligament fibers run from bone to cementum within the socket. The gingiva is firmly attached to the

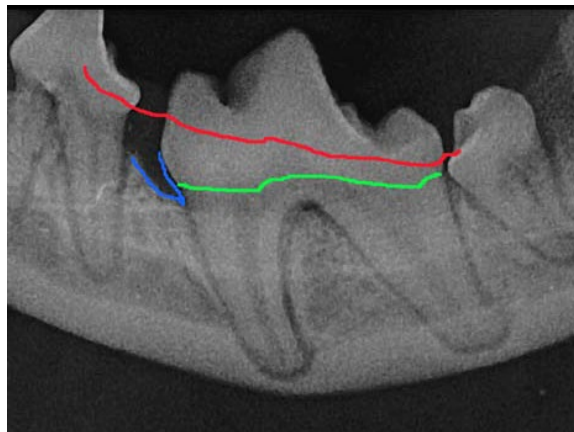
bone up to the top of the socket and then attached to the cementum between the top of the socket and the cemento-enamel junction. Then, the free gingiva extends above the cemento-enamel junction a bit to lie passively against the enamel. This space between the free gingiva and the enamel is known as the gingival sulcus. This is a crucial point to understand – periodontal ligament and gingiva will not attach to enamel! How deep should the gingival sulcus be? Well that depends on the size of the animal and the tooth as I explain in this paper on [probing depths](#).

So what happens if a tooth fails to erupt fully? Then more of the enamel-covered crown is trapped below the gum line and maybe even with the bony socket. Since the gingiva and periodontal ligament will not attach to the buried enamel, the effective “gingival sulcus” is far deeper than it should be and this can be a haven for bacteria. The inflammation incited by subgingival bacteria around the buried portion of the crown of an under-erupted tooth is known as pericoronitis. And then that can be a foot-in-the-door for periodontal disease to work its way down the root of the tooth.

Sometimes under-eruption is due to mechanical impediment to eruption (as shown at the bottom of page four). Sometimes it just happens for no apparent reason. For example, I find that the canine teeth of small brachycephalic dogs (Boston terriers, pugs, French bulldogs...) are often dramatically under-erupted despite any mechanical obstruction to their eruption. They simply fail to erupt properly and so there is no pro-active action we can take to get them to erupt.

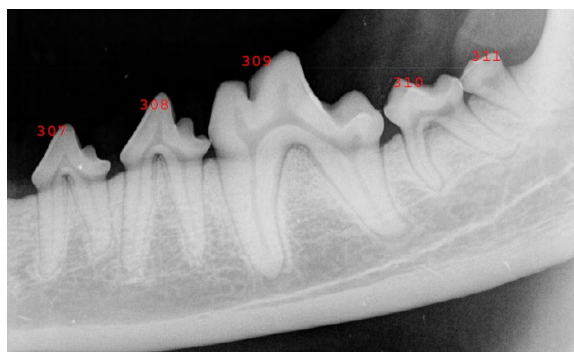
In some cases we can do surgery to expose the crown properly (crown lengthening surgery).

In the following radiograph of a nine-month-old shih tzu, we see the lower left 4th premolar and 1st and 2nd molar teeth. The less-important 4th premolar has erupted well, but the mesial (forward) aspect of the 1st molar is under-erupted. The green line represents the cemento-enamel junction. The red line is the gingival margin. The blue line is highlighting a “V-shaped” cleft in the bone at the mesial aspect of the 1st molar.



Also notice how deep into the mandible the mesial root of that molar extends – there is very little solid bone ventral to that root tip. Let’s take a short detour here.

Each mandible (left and right) is like a three dimensional beam of bone. It has length and height but not much width (from lip side to tongue side). Then it is perforated with holes which are the sockets that hold the tooth roots and this creates weak spots subject to fracture. In a large dog with well proportioned teeth, the roots are relatively short compared to the height of the bone as seen in this image of the left mandible of a properly constructed dog.

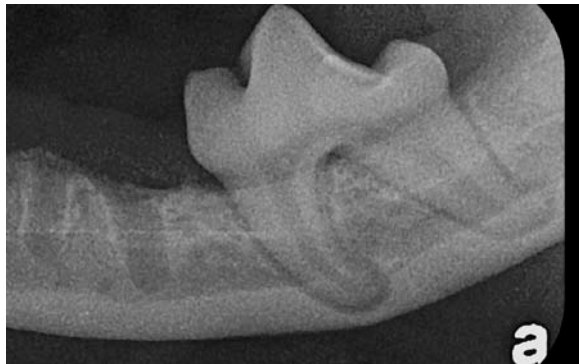


There is considerable uninterrupted bone below the tooth roots to give this mandible some strength. Now look at the radiograph of that shih tzu again and see how the mesial root of the canine tooth goes almost right through the ventral cortex (the dense layer of bone along the bottom of the jaw).

If the under-eruption of that molar were to be left unmanaged, there is a real risk that periodontal disease would develop at the bottom of that cleft and start working its way down the

root, destroying bone along the way, weakening the jaw more and more. And then the jaw might fracture under minor stress and there would not be much left to put back together to get healing.

To prevent that catastrophic outcome, I removed the 4th premolar and the 2nd molar (it was also under-erupted with respect to the gingiva), recontoured the bone mesial to the 1st molar so that when I was finished, the cemento-enamel junction was above the level of the bone (where it should be) and the mesial aspect of that crown was out in the open.



This is still a shih tzu, so she is still at risk for periodontal disease and jaw fracture, but the risk has been reduced (more on jaw fractures below).

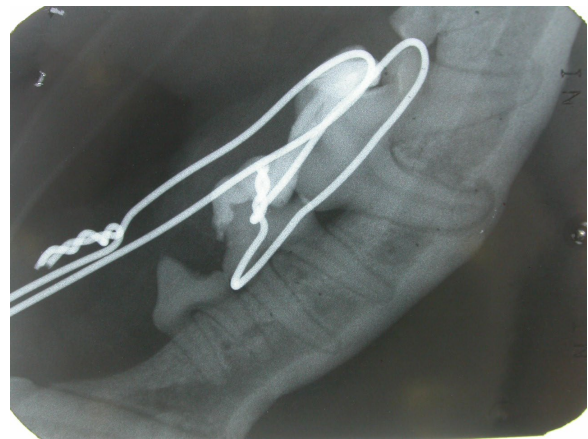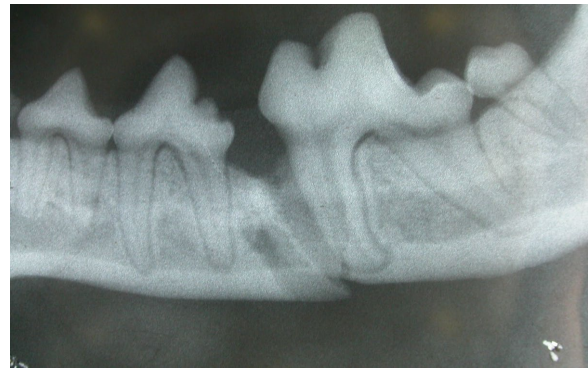In other cases, the best bet is to simply extract the under-erupted tooth. Keep in mind that a tooth that has failed to erupt properly is going to be rather functionally useless, but it is going to be a liability. So to optimize oral health, it should come out.

Mandibular Fractures

I see a fair number of traumatic mandibular fractures. Certainly any dog is at risk if the trauma is dramatic enough. But with small brachycephalic dogs whose tooth roots are very large in proportion to the mandible, it takes very little stress to induce a fracture. We have seen small brachycephalic dogs who have suffered mandibular fractures from simply falling off the sofa and banging their chin on the floor. [This paper](#) profiles a case of a one-year-old Boston terrier with just that history. The dog was exhibiting pain after falling off of the sofa.

And here are pre-operative and post-healing radiographs of a 1-year-old shih tzu with a more

obvious presentation of a mandibular fracture in the same location.



Loose Mandibular Symphysis

Mammals all have two mandibles; one left and one right. In pigs and primates, these two bones fuse together at the centre of the chin to effectively form one bone with no movement between them. In dogs and cats, the two mandibles remain separated from each other but are connected by a layer of tough fibrous tissue. This creates what is referred to as a false joint or synarthrosis between the two mandibles. For a large, predatory animal such as a wolf, or lion, who might be tackling another large animal, this false joint is an evolutionary adaptation that allows some movement between the mandibles during the struggle to reduce the risk of fracture (shock absorption). In large, well constructed dogs, the symphysis tends to be quite thin and firm (very little if any movement between the mandibles).

In small brachycephalic dogs, the symphysis can be very wide indeed with a lot of movement between the mandibles. I discuss this more in this paper, [Focus on the Mandibular Symphysis](#).

Take a piece of light string and stretch it between your two hands. Now pull of the ends to try to break the string. Next, (with a new piece of string if you managed to break the first piece) bring your hands together and then rapidly move them away from each other. I bet it was easier to break the string when you put slack in it first and jerked on it rapidly. This is the concern with a loose symphysis. Once it is loose (once there is some play in it), it will tend to stretch and get looser over the years. And a loose symphysis is at greater risk of rupture just like a slack string is at greater risk of snapping under stress.

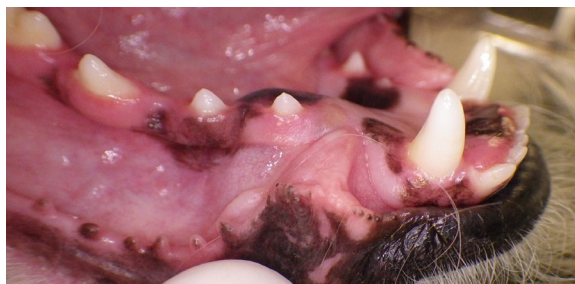While an acutely ruptured symphysis requires treatment, there is nothing you can do to tighten a physiologically loose symphysis. It is just one of the many crosses that a brachycephalic dog must bear.

Dentigerous Cysts

This is another condition for which I have a [separate paper](#). Dentigerous cysts are fluid-filled structures that can develop around the crown of a tooth that has remained un-erupted. While they can occur in any breed, they are far more common (in my experience) in brachycephalic breeds. Boxers, for example, are very prone to having dentigerous cysts form around un-erupted 1st premolar teeth (sometimes it is an extra unerupted tooth – go see my [paper on boxers](#) if you have not already done so).

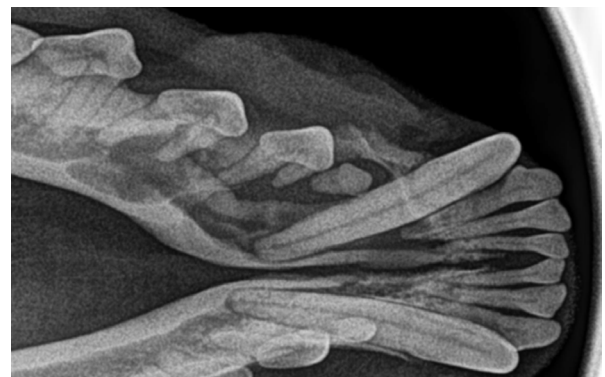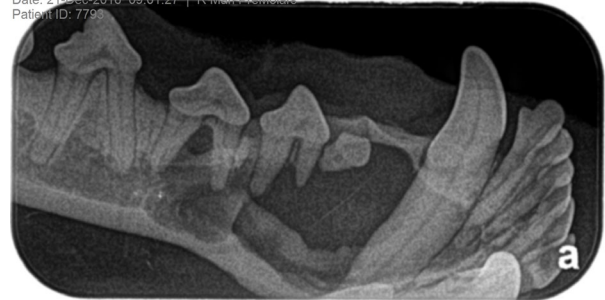The following images are from the right rostral mandible of a 6.5-year-old shih tzu with a dramatic dentigerous cyst centered around an unerupted lower right 1st premolar tooth.

Visually, there was no great sign of trouble other than the apparent absence of the lower 1st premolar (always an indication to get intra-oral dental radiographs).

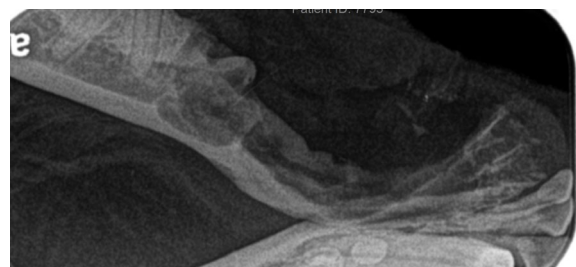

The teeth look very clean because the referring veterinarian had just done a cleaning a few weeks prior and had (quite properly) done whole-mouth intra-oral dental radiographs and that is when he found this:

Date: 21-Dec-2016 09:01:27 | R-Mon-ProMolars
Patient ID: 7739



The 1st premolar was present but unerupted and the cyst had destroyed the bone supporting the incisors, the canine and back to the 3rd premolar. All of those teeth required extraction along with curettage of the cyst lining prior to wound closure.



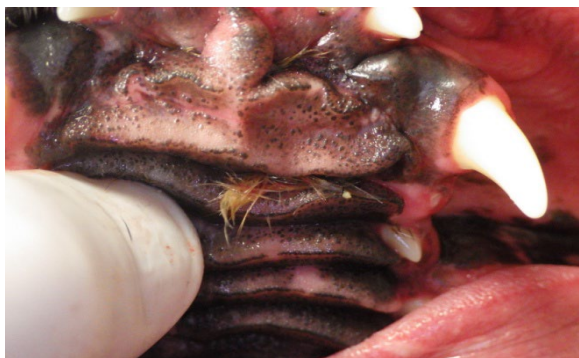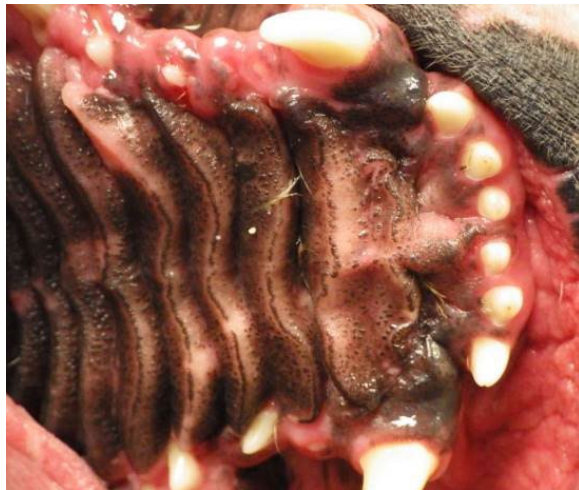This cyst was 100% preventable if that unerupted lower 1st premolar had been detected and removed when the dog was anesthetized to be neutered at six months of age.

Furry Palate

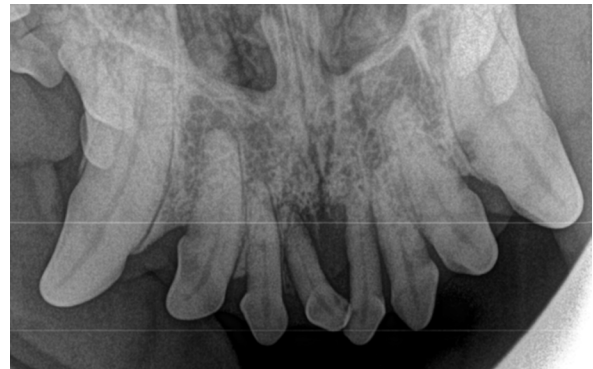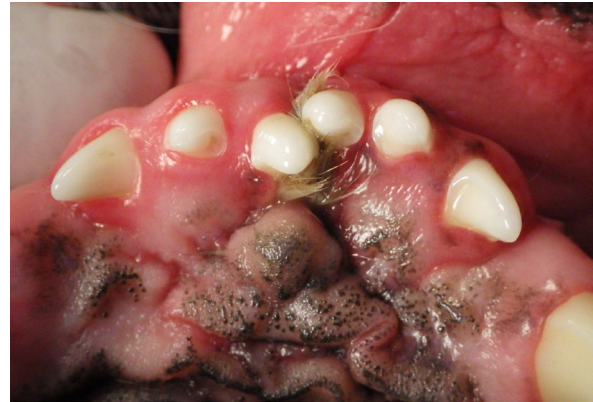Go back to page 2 to see the images of the palates of an Australian Shepherd and a pug. Starting with the Aussie, the soft tissue that covers the hard palate is ridged (I don't know

why, but it is). These waves of tissue are called the palatal rugae. If you view this in cross section, it is like a series of peaks and valleys. In a properly constructed mouth, the peaks are far apart and the valleys are open so they do not trap debris.

In a brachycephalic mouth, all of that soft tissue is bunched up (I would say “accordianed, my UK friends would say concertinaed). That means the peaks are crammed together and the valleys are closed, so they trap food, fur, debris, bacteria. This can result in a constant ulcerative palatitis (inflammation of the palate) hiding at the bottom of the valleys. Here are some still images of this problem in a 5.5-year-old boxer.



And below we have a four-year-old English bulldog who was presented with a complaint of horrendous oral malodour.



In this instance, it was deep folds in the mucosa rostral to and around the incisive papilla. This was trapping fur and had led to end-stage periodontal disease of the four middle incisors.

I took out those four incisors, debrided and closed the wound along with lots of other work. Then I saw her again at 6.5-years-of-age and shot this video – [furry palate](#).

I do not have a cure for furry palate. We cannot remove the palatal mucosa, we cannot stretch the maxilla to a desirable length. All I can suggest to owners of these dogs is that when they are brushing their dog's teeth (daily) that they also sweep the roof of the mouth to try to keep those closed valleys clean.

Conclusion

Obviously, there are many brachycephalic dogs and cats in existence currently and there will be more in the future. I have no serious expectation that my campaign to end their continued propagation will succeed within my life time. That means that there are millions of dogs and cats out there suffering from many of the issues

outlined in the preceding pages. And they need our care (lots of it). While we cannot make these mouths normal, there is a lot we can do to minimize the oral consequences of brachycephalism. Making the best of a (really, really) bad design will improve oral health and in so doing, will have a dramatic impact on quality of life.

Do NOT accept the pathology in a brachycephalic mouth as an inevitability. Never say “that is normal for the breed”. Recognize that deformed is deformed regardless of the arbitrary (and often ignored, misinterpreted or bastardized) breed standards. If it would be wrong in a Lab mouth, it is wrong in a boxer mouth and it needs assessment and treatment.

And to those who still defend brachycephalic breeds (and mixes), I offer the following manifesto -

<https://www.facebook.com/stopbrachycephalism/posts/1007849159313220>.