

# Vital Pulpotomy vs. Total Pulpectomy

As I have mentioned several times in past issues of The CUSP, broken teeth are a serious problem that definitely require treatment of some sort. In this item, I will assume that you understand that and I am going to concentrate on treatment planning for these fractured teeth.

For now, let us consider the simplest of cases in which a dog has taken the tip off a canine tooth, The pulp is exposed, but there is no damage near or below the gumline and the remaining two thirds of the crown is intact.

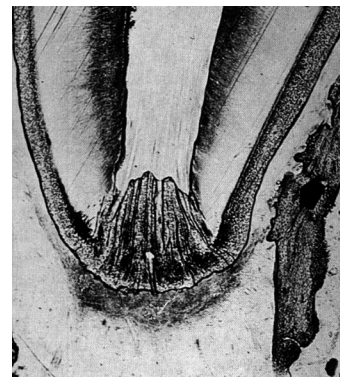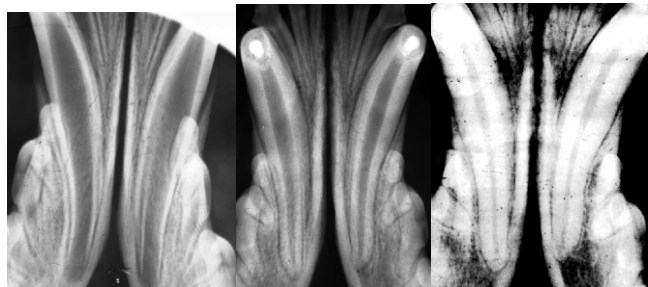
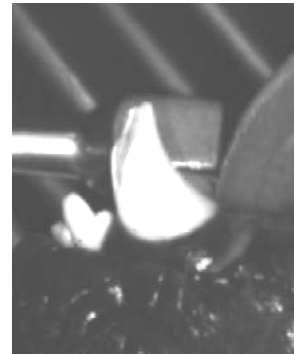In cases where the pulp is exposed, there are two main treatment options to consider. The first is extraction. This would achieve the objectives of removing a source of considerable pain as well as a conduit of infection. The other option is endodontic treatment of some type.

Endodontic treatment options include *total pulpectomy* or *partial vital pulpotomy*. Each option has its advantages and disadvantages, indications and contra-indications. To understand some of these, it is important to know something of dental development and physiology

When a permanent tooth is developing within the jaw of a young animal, it is constructed from the outside-in. That is to say, the enamel of the crown is produced early in the process so that the outside dimension of the crown is established early. Once the enamel is formed, the tissue that made it goes dormant and no more enamel can ever be produced for that tooth.

On the inside of the tooth is the pulp (blood vessels, nerves, lymphatics and various free cellular elements). Lining the inside wall of the developing tooth is a single layer of low columnar cells known as odontoblasts. These cells produce dentin, which is the hard tissue that makes up the bulk of the tooth. During pre-eruptive development and during eruption, the odontoblasts produce primary dentin. Once the tooth had developed to its final length, the odontoblasts produce secondary dentin such that the pulp chamber inside the tooth gets smaller as the wall of the tooth gets thicker. This progression can be seen in the series of radiographs, all of the same animal and taken at 6, 14 and 32 months of age.

In the first radiograph (six months of age), the tooth is still erupting, the dentin wall of the crown and root is very thin and the apex (root tip) has not yet formed. At 14 months, the tooth is fully erupted, the apex has closed and the dentin walls in the root and crown are much thicker than at six months. By 32 months, the pulp chamber is smaller still and the root wall thick enough for these teeth to be considered 'mature'. As long as the pulp remains healthy, the odontoblasts will continue to produce secondary dentin and the pulp chamber will get progressively narrower as the animal ages. This process occurs in most carnivores and omnivores.

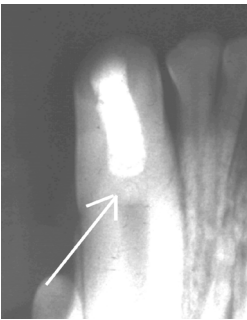


In dogs and cats, after the apex is ‘closed’, there are still several tiny channels through which the pulp communicated with the rest of the body. This collection of channels constitutes the apical delta.

Another point to keep in mind is that dentin is elastic. Due to a higher collagen and water content than enamel, it is not as hard, but neither is it as brittle. Therefore, a living tooth can bend a little without fracturing. This elasticity is thought to depend on a continuing source of moisture as supplied by the vital pulp.

With that understood, let’s look at vital pulpotomy and total pulpectomy.

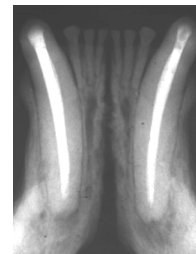
In *vital pulpotomy*, also known as *partial vital pulpectomy*, only the coronal portion of the pulp is removed. Typically, a sterile bur, in a high-speed hand piece is used to amputate the pulp to a depth of about 6-8 millimeters. The rest of the pulp is left inside the tooth. Next, various dental materials are placed inside the chamber on top of the pulp stump to protect the pulp and to seal the tooth against the ingress of bacteria that would kill the pulp. Typically, the material placed in direct contact with the freshly cut pulp stump is a calcium hydroxide preparation. The very high pH actually causes a surface necrosis of the pulp it touches. Undifferentiated free cells in the pulp below the zone of necrosis are stimulated to become odontoblasts and start producing dentin (this dentin produced in response to some irritation is known as tertiary or reparative dentin). The bulk of the pulp inside the tooth remains unaffected by the treatment and so normal secondary dentin production continues as before within the rest of the tooth.



This radiograph shows the dentin bridge that has formed between the vital pulp and the restorative materials placed inside the pulp chamber of the crown of this canine tooth. As the animal ages, the chamber in the root should get smaller due to secondary dentin production.

In *total pulpectomy*, the entire pulp is removed from the tooth and the chamber (root canal) is filled with dental materials. Once this is done, the odontoblasts are all gone – there can be no more dentin production of any kind in the treated tooth.

Its wall will never get any thicker no matter how long the animal lives. This radiograph of a cat mandible shows the mandibular canines after the canals have been debrided and obturated (filled), but prior to final restoration of the access holes in the crowns.



The advantages to partial vital pulpectomy and direct pulp capping include:

- usually faster and cheaper than total pulpectomy,
- keeps the pulp intact so the tooth can continue to mature,
- maintains a source of moisture to the dentin, helping to keep it elastic (flexible).

The big disadvantage is, it may not work! If a partial vital pulpotomy and direct pulp capping is done and it fails, that means that the pulp dies anyway. During the time the pulp is dying, there will be acute toothache. Once the pulp is dead, you have the same problems as you get with an untreated broken tooth – chronic pain and infection. In fact, with the crown sealed with a bonded restoration, any pressure that builds up inside the tooth (due to gas production by bacteria) must be released through the apical delta.

To monitor for signs of success or failure, it is very important that the tooth be re-radiographed (intra-oral dental radiographs under general anesthesia) at least once (six to twelve months post-operatively) and preferably every few years thereafter. In humans, pulp-capping procedures have been known to fail as much as twenty years post-operatively. Therefore, once a tooth has had a

partial vital pulpotomy and direct pulp-capping, it requires long-term follow-up and its prognosis always remains open.

The main advantages of total pulpectomy are the obverse of the disadvantages of pulpotomy. Once a full root canal is done, there is no pulp left in the tooth to cause any trouble. Therefore, you do not have to worry about how the pulp is doing. Follow-up radiographs are still recommended to assess the health of the periapical tissues, but the chances of things going badly down the road are greatly reduced.

The disadvantages of total pulpectomy include:

- cessation of dentin production so tooth wall never gets thicker,
- theoretical gradual dehydration of dentin causing tooth to become more brittle over the years (not proven beyond doubt),
- usually takes longer than pulpotomy and so costs more in the short term.

### **So how do I decide which treatment to choose when I am presented with a fractured tooth?**

I consider several factors in treatment planning for a fractured tooth. I need to know how old the animal is (vis-à-vis root wall thickness), how long ago the tooth was damaged (vis-à-vis how long the pulp has been exposed to oral bacteria and mechanical trauma from chewing) and how committed the owners are to follow-up (vis-à-vis getting the necessary radiographs to monitor the tooth in the future).

In a young dog or cat (less than 18 months of age usually) with a recent fracture (less than 48 hours), I like to do partial vital pulpotomy and direct pulp capping to keep the tooth alive, allowing it to grow in strength and maintain its elasticity. For this to be possible, it requires **immediate action!** So if you see a patient that fits this profile, **drop everything and call me immediately!** I will do everything I can to see the patient without delay as the chances of success really depend on fast action.

In a mature animal, I usually go straight to total pulpectomy. Once the animal is two years old or more, the tooth has the majority of its strength, so keeping it alive is of less value than in a younger patient. Also, the smaller pulp of a mature patient is far less resilient, it has fewer undifferentiated cells to produce the dentin bridge and it is less likely to survive the initial trauma and the treatment itself. So the prognosis for a partial vital pulpotomy in a mature animal is not good.

There are, of course, exceptions to these generalities. There are also animals that fall into gray zones (between 18 and 24 months of age or fractures 3 to 5 days old). These need to be evaluated carefully, in consultation with the owners, to decide what is most appropriate in their specific situation. Sometimes I do the pulpotomy and sometimes I do the full root canal and sometimes I extract the tooth.

I should also mention that there is a procedure to rescue immature teeth that have already suffered pulp necrosis. For example, if dog fractures as canine tooth while it is erupting and the apex is still wide open and the condition goes untreated, allowing the pulp to become necrotic, it is not possible to do a partial pulpotomy. Nor does the thin root wall and open apex allow for standard root canal therapy.

***A young animal with a recent dental fracture needs IMMEDIATE attention if we are to save the tooth!!!***

In these cases, a procedure known as *apexification* can be done. Here, the necrotic pulp is gently removed from the canal. The canal is gently lavaged with saline and then it is packed with a calcium hydroxide paste and the hole in the crown restored. The calcium hydroxide paste should stimulate the tissues around the root tip to produce osteoid or BLCL (bone-like, cementum-like) tissue, thus forming a closed apex.

The tooth is re-radiographed and the calcium hydroxide paste dressing changed every 3 to 6 months until a solid apex has formed, at which time the canal is again debrided and then filled in the manner typical of regular root canal treatment. This preserves the tooth, but it will always be thin walled in both crown and root and so my own opinion is that it is a heroic effort with a dubious long-term prognosis. It takes several anesthetics and surgeries and so ends up being quite expensive. It is far better to treat these immature teeth right away and keep the pulp alive.